

wellcome  
collection

Welcome  
to the  
Museum

ADMIT ALL

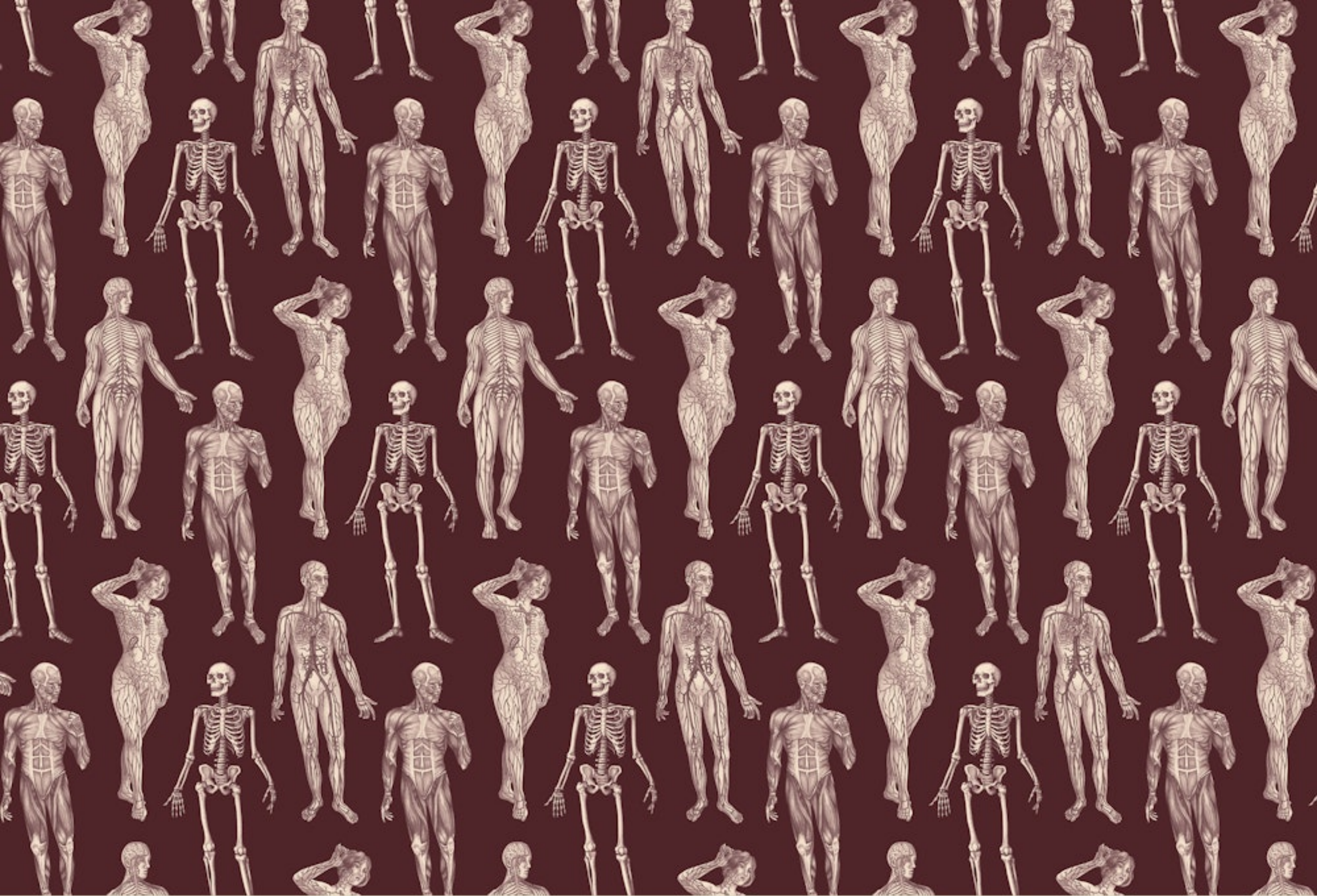# Anatomicum

Curated by KATY WIEDEMANN and JENNIFER Z PAXTON

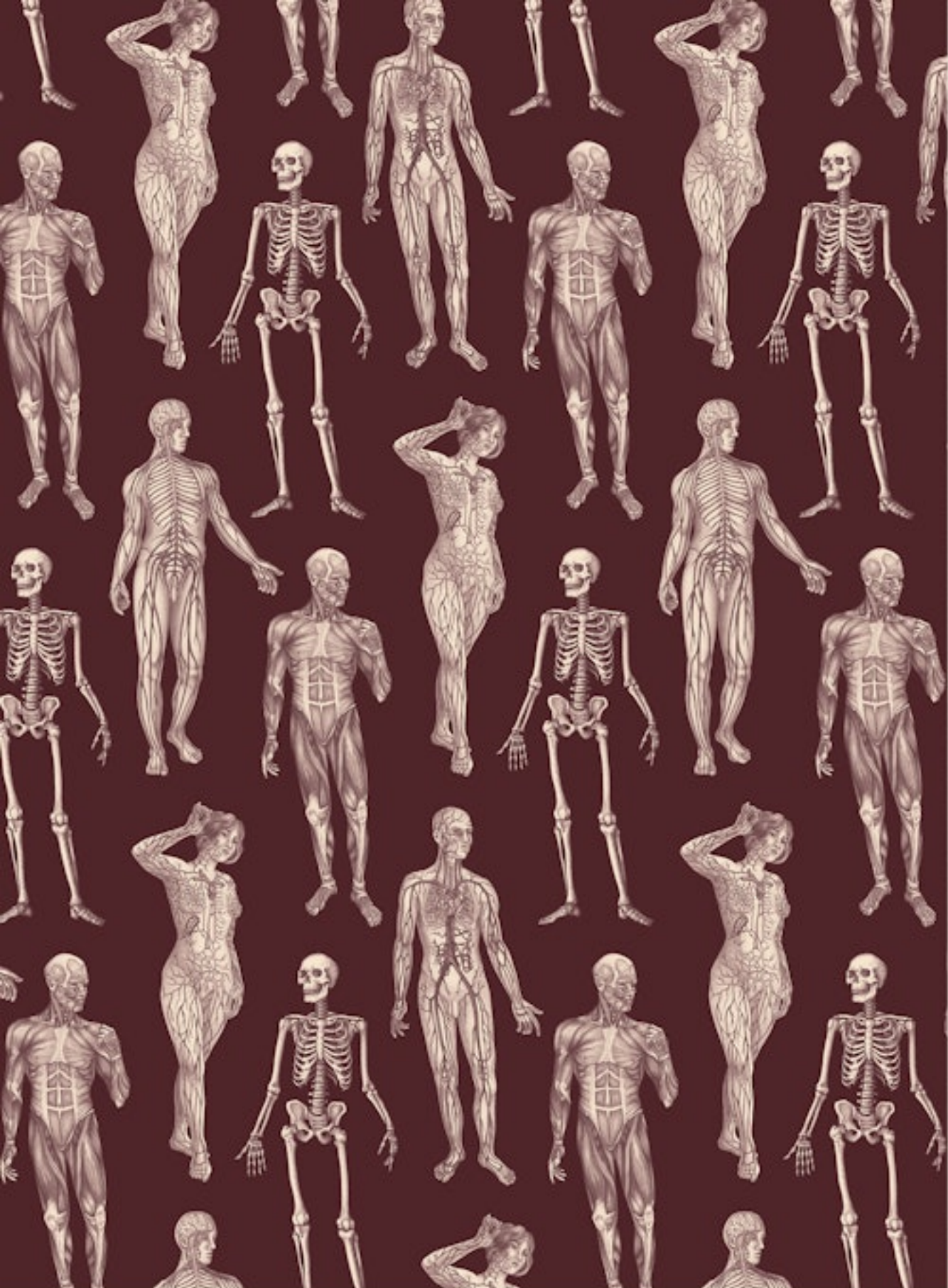


B  
I  
G  
P  
I  
C  
T  
U  
R  
E  
P  
R  
E  
S  
S









# *Anatomicum*



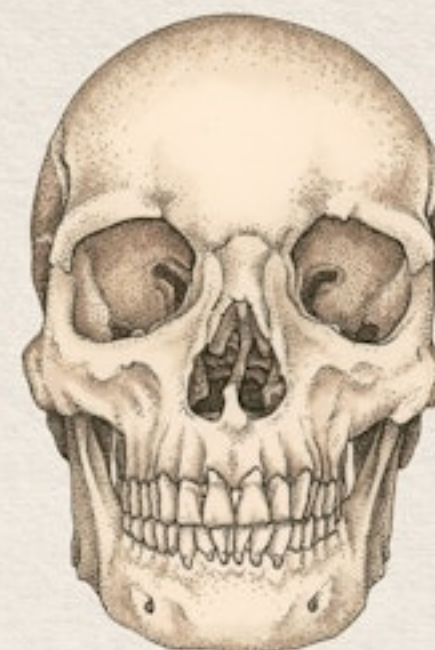Welcome  
to the  
Museum

ADMIT ALL

# Anatomicum

Illustrated by KATY WIEDEMANN

Written by JENNIFER Z PAXTON



*For my parents – K.W.*

*For Hannah – J.P.*

BIG PICTURE PRESS

First published in the UK in 2019 by Big Picture Press,  
an imprint of Bonnier Books UK,  
4th Floor, Victoria House  
Bloomsbury Square, London WC1B 4DA.  
Owned by Bonnier Books  
Sveavägen 56, Stockholm, Sweden  
[www.bonnierbooks.co.uk](http://www.bonnierbooks.co.uk)

Illustration copyright © 2019 by Katy Wiedemann  
Text copyright © 2019 by Jennifer Z. Paxton  
Design copyright © 2019 by Big Picture Press

5 7 9 10 8 6 4

All rights reserved

ISBN 978-1-78741-492-1 (hardback)  
ISBN 978-1-78741-614-7 (eBook)

This book was typeset in Gill Sans and Mrs Green  
The illustrations were created with ink and watercolour

Edited by Ruth Symons  
Designed by Kerin Hood  
Production Controller: Neil Randes

Printed in China



Published in association with Wellcome Collection,  
part of Wellcome, 215 Euston Road, London NW1 2BE.  
[www.wellcomecollection.org](http://www.wellcomecollection.org)

**wellcome  
collection**

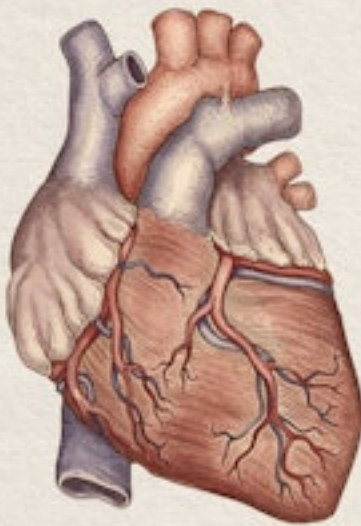Wellcome Collection is a free museum and library that aims to challenge how we all  
think and feel about health, creating opportunities for people to think deeply about the  
connections between science, medicine, life and art. It is part of Wellcome, a global charitable  
foundation that exists to improve health for everyone by helping great ideas to thrive.



B P P



# Preface



Underneath our skin lies the incredible world of the human body; a living machine constructed from hundreds and thousands of parts, all working together to make us who we are.

Exactly how our bodies work has fascinated scientists for centuries. Their study of the body's structure – called anatomy – provides the basis for all of our medical understanding.

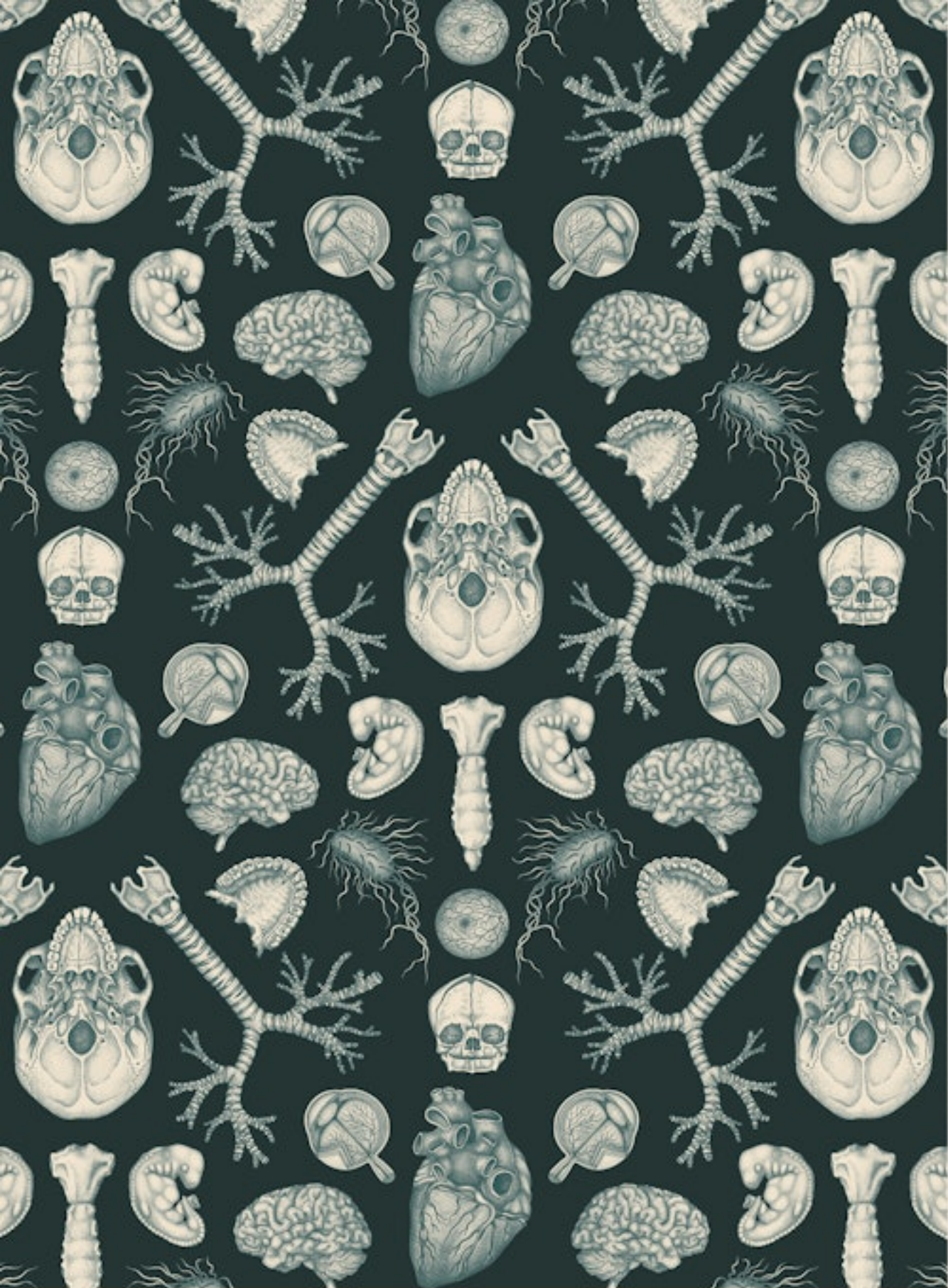The word anatomy comes from the ancient Greek *anatomē*, meaning 'to cut up'. It has been studied since the earliest recorded periods of history, as long ago as 1600bc. In certain societies, the art of dissection – the 'cutting up' that gives anatomy its name – was forbidden, and animal remains were dissected instead. This led to some mistakes in the understanding of the human body until years later, when scientists such as Leonardo da Vinci and Andreas Vesalius made detailed drawings of their findings. Today dissection is still used by scientists and doctors as the primary way of studying the body, through carefully controlled legal processes allowing individuals to donate their body to science after death.

Beside moral and religious concerns about dissection, there were other obstacles to early studies of anatomy and medicine. Before the development of the microscope in the 1590s, bacteria and other tiny cells were unknown to scientists. Instead, doctors believed that bad airs called 'miasmas' were to blame for illnesses, and sadly diseases which can easily be cured today killed thousands of people.

Today, we are entering an exciting new era in anatomy. Technological improvements in imaging enable us to see the human body in greater detail than ever before, and the science of tissue engineering (building new tissues and organs) could help doctors find new treatments to help their patients. Every year, research leaps forwards, cures are discovered and our knowledge improves. But it all starts here, with the basics of anatomy, and the study of the incredible human body.

**Dr Jennifer Z Paxton**  
The University of Edinburgh





1

## Entrance

*Welcome to Anatomicum; Building Blocks of the Body*

7

## Gallery 1

# The Musculoskeletal System

*The Skeletal System; Bones; The Skull; Joints;  
Connective Tissues; The Muscular System;  
Muscle Tissue; Muscles; The Hands;  
Muscles; Facial Expression*

27

## Gallery 2

# The Cardiovascular & Respiratory Systems

*The Cardiovascular & Respiratory Systems;  
The Heart; Blood; The Respiratory Tract; The Lungs*

39

## Gallery 3

# The Digestive & Urinary Systems

*The Digestive System; The Mouth & Throat;  
The Teeth; The Stomach; The Intestines;  
The Liver; The Pancreas & Gallbladder;  
The Urinary System; The Kidneys*

59

## Gallery 4

# The Nervous System & Special Senses

*The Nervous System; The Central Nervous System;  
The Peripheral Nervous System; The Eyes;  
The Ears; The Nose & Tongue; The Skin*

75

## Gallery 5

# The Immune & Lymphatic Systems

*The Immune & Lymphatic Systems; Disease & Defence*

81

## Gallery 6

# The Endocrine & Reproductive Systems

*The Endocrine System; Puberty;  
The Male Reproductive System; The Female  
Reproductive System; Development of a Baby*

93

## Library

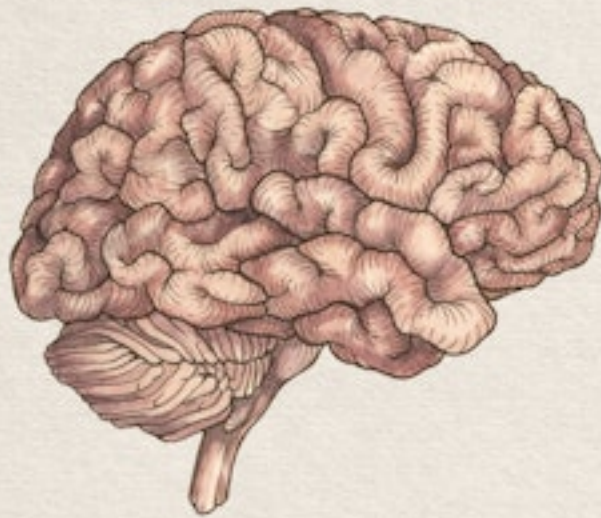*Index; Curators;  
To Learn More*



ANATOMICUM

*Entrance*

# Welcome to *Anatomicum*



Have you ever wondered what the inside of your body looks like? Think what it would be like if you could see it from the inside out. Imagine you could watch your heart beating, witness your skin cells growing or pinpoint the part of your brain where a thought takes shape. Now you can, within the pages of *Anatomicum*.

Open twenty-four hours a day, seven days a week, this unique museum isn't like anywhere you've ever been. As you walk its halls and corridors, you will be transported right around the human body, seeing it in vivid detail like never before.

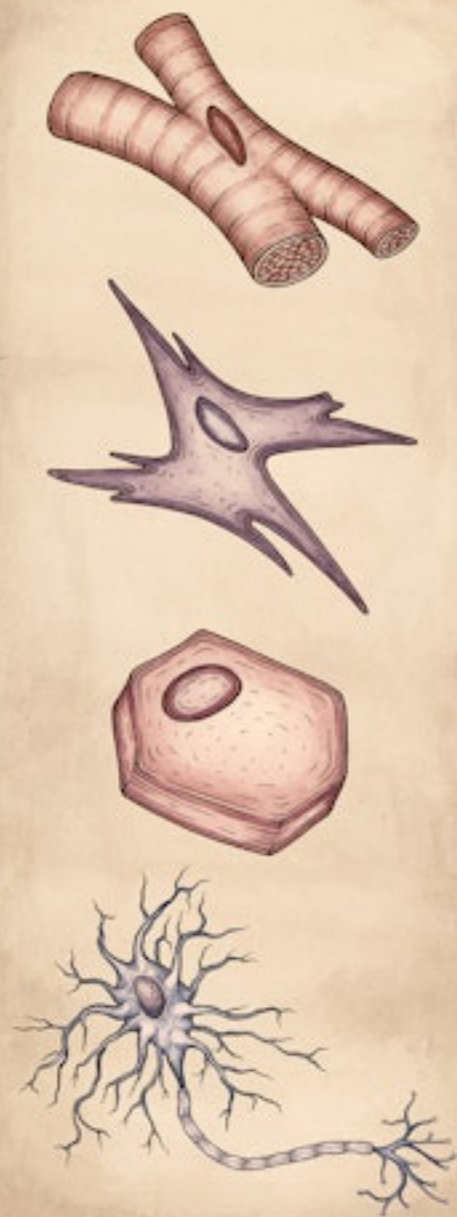In each gallery you will encounter one of the body's major systems. For example, you can visit the Musculoskeletal System Gallery to discover the tissues that help us to move, or arrive at the Nervous System Gallery to examine the structure of the human brain. The exhibits will allow you to peer beneath the skin and view the organs that help us breathe, or see how food is transported and processed through the long passages of our guts. You will also learn how babies develop from a single cell, and how our bodies change as we grow up.

As you explore the museum, consider how your own body is constantly working. Your heart keeps your blood pumping. Your lungs bring air in and out of your body. Every step you take – even standing still – requires actions of your muscles. Your eyes enable you to read the text for each exhibit and your brain processes all of the new information at astonishing speeds. Your body is amazing.

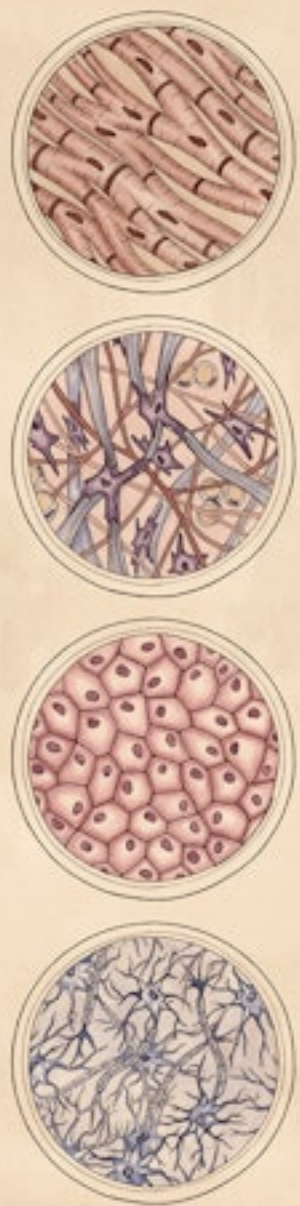
So enter *Anatomicum* here to begin your voyage of discovery, and uncover the wonders and secrets of the human body.



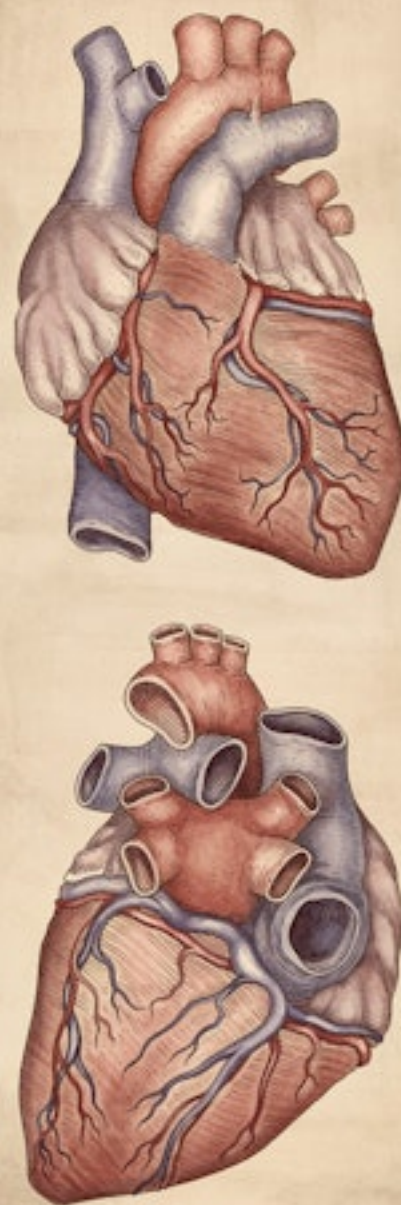
*Fig. 1 Cells*



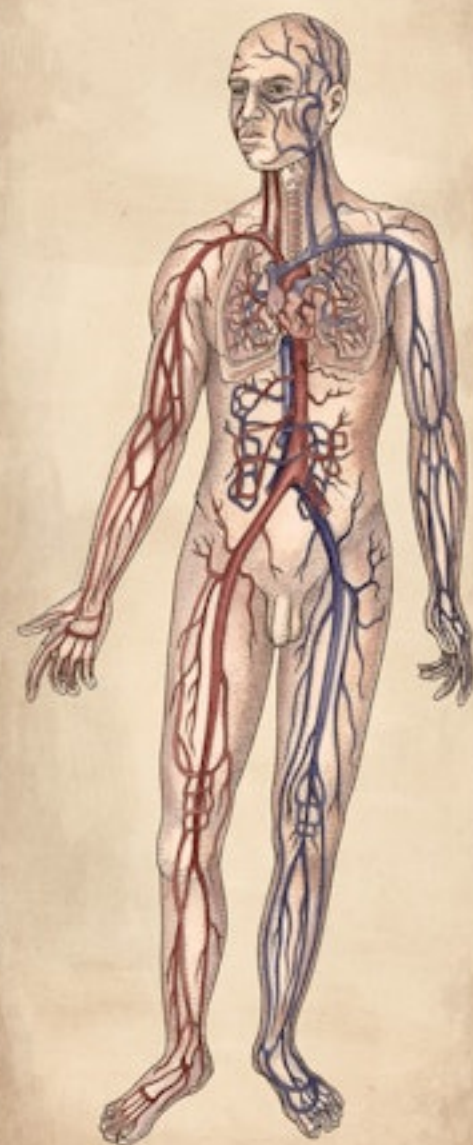
*Fig. 2 Tissue*



*Fig. 3 Organ*

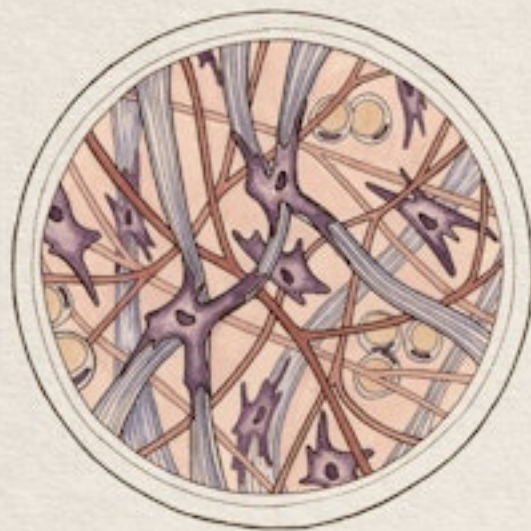


*Fig. 4 System*





# Building Blocks of the Body



The human body is intricately detailed – woven together from individual organs, tissues, blood vessels, nerves and tiny cells. In anatomy, the different parts of the body are arranged from the smallest to the largest parts, in a simple structured order.

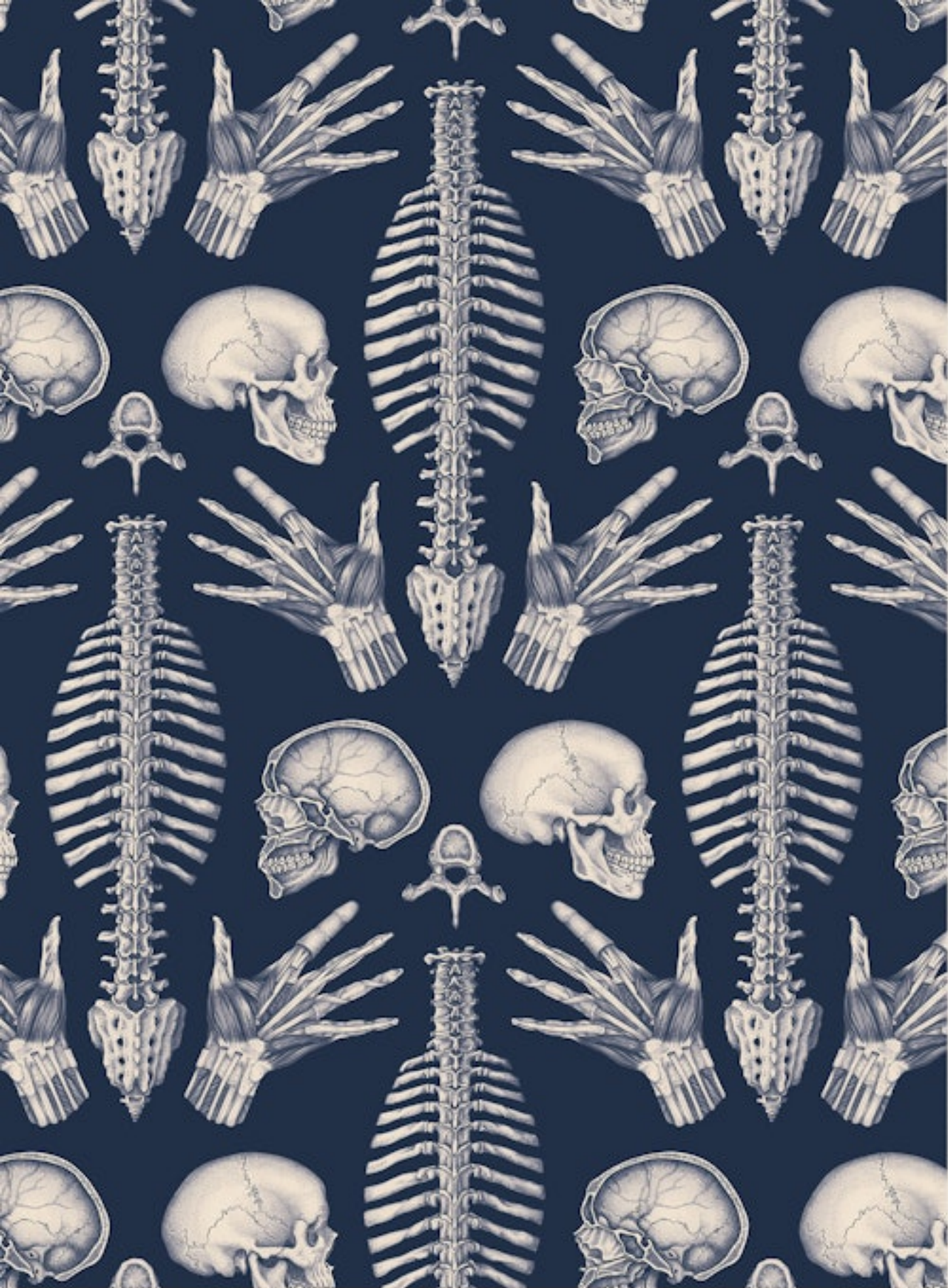The smallest individual building blocks of the body are the cells. An astonishing 38 trillion of them exist in the human body, each with its own special job to do. Almost every one contains DNA (deoxyribonucleic acid), the coded genetic information that determines our characteristics and makes us all unique. Individual cells are too small to be seen by the naked eye and can only be viewed using microscopes.

Groups of cells join together to make body tissues, which are large enough to be seen without a microscope. Epithelial tissues line the inside of organs and tubes, and cover the outer surface of the skin. Muscle tissue is like the machinery of the body, making up the structures that help us to move. Nervous tissue is important for communication throughout the body, linking its different parts to the central control centre of the brain. Lastly, connective tissues help to link or support different parts of the body and hold it together.

At the next level up, multiple tissue types combine to make organs: individual parts of the body with defined names and functions, such as the heart, lungs, brain or kidneys.

Finally, several organs link up to make body systems. There are 11 systems in the human body: skeletal, muscular, digestive, cardiovascular, respiratory, urinary, nervous, integumentary, immune, reproductive and endocrine. Each system looks after a series of related jobs, such as breathing in the respiratory system or processing food in the digestive system. Although they have individual roles, the systems all function together in harmony to keep our bodies working properly.

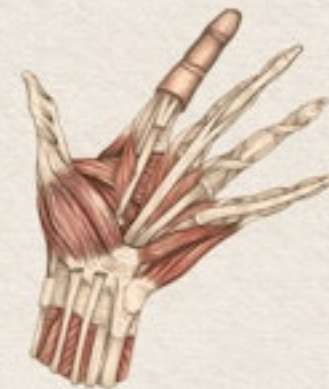



ANATOMICUM

Gallery 1

# The Musculoskeletal System



*The Skeletal System*  
*Bones*  
*The Skull*  
*Joints*  
*Connective Tissues*  
*The Muscular System*  
*Muscle Tissue*  
*Muscles: The Hands*  
*Muscles: Facial Expression*



# The Skeletal System

Providing the framework for the entire human body is the skeleton. This hard but flexible scaffold gives us our overall shape, supports the muscles, protects the body's soft inner organs and constantly manufactures new blood cells. The entire skeleton is made up of 206 individual bones, which link together at areas called joints. These keep the bones of the skeleton fixed to each other, while also allowing us to move.

Anatomists split the skeleton into two parts: the axial skeleton, which supports the upper body and protects the inner organs; and the appendicular skeleton, made up of the bones in the limbs and pelvis. The axial skeleton incorporates all the bones of the head and trunk, where its primary role is to protect the brain, the sensory organs (eyes, ears and nose), the heart and the lungs. It also includes the vertebral column, or spine, a long row of 33 bones called vertebrae which encase the delicate spinal cord. Stacked together, the vertebrae make a curved, flexible pillar, which can bend forwards, backwards or side-to-side. The spine connects to the skull at its first (or top) vertebra, which is named after the figure Atlas from ancient Greek mythology. Atlas was condemned to bear the weight of the whole sky on his shoulders, just as the atlas vertebra has to support the weight of the skull and brain.

The bones of the upper limbs – the arm, forearm, wrist and hand – have a greater range of movement than any other part of the skeleton, combining strength with dexterity so that we can perform tasks as varied as threading a needle and batting a ball. In contrast, the bones of the lower limbs – in the thigh, leg, ankle and foot – mainly provide stability and support our weight as we walk, stand or run. Key to this is the longest and strongest bone in the human body: the femur or thigh bone.

## Key to plate

### 1: Skeleton, seen from the front (anterior view)

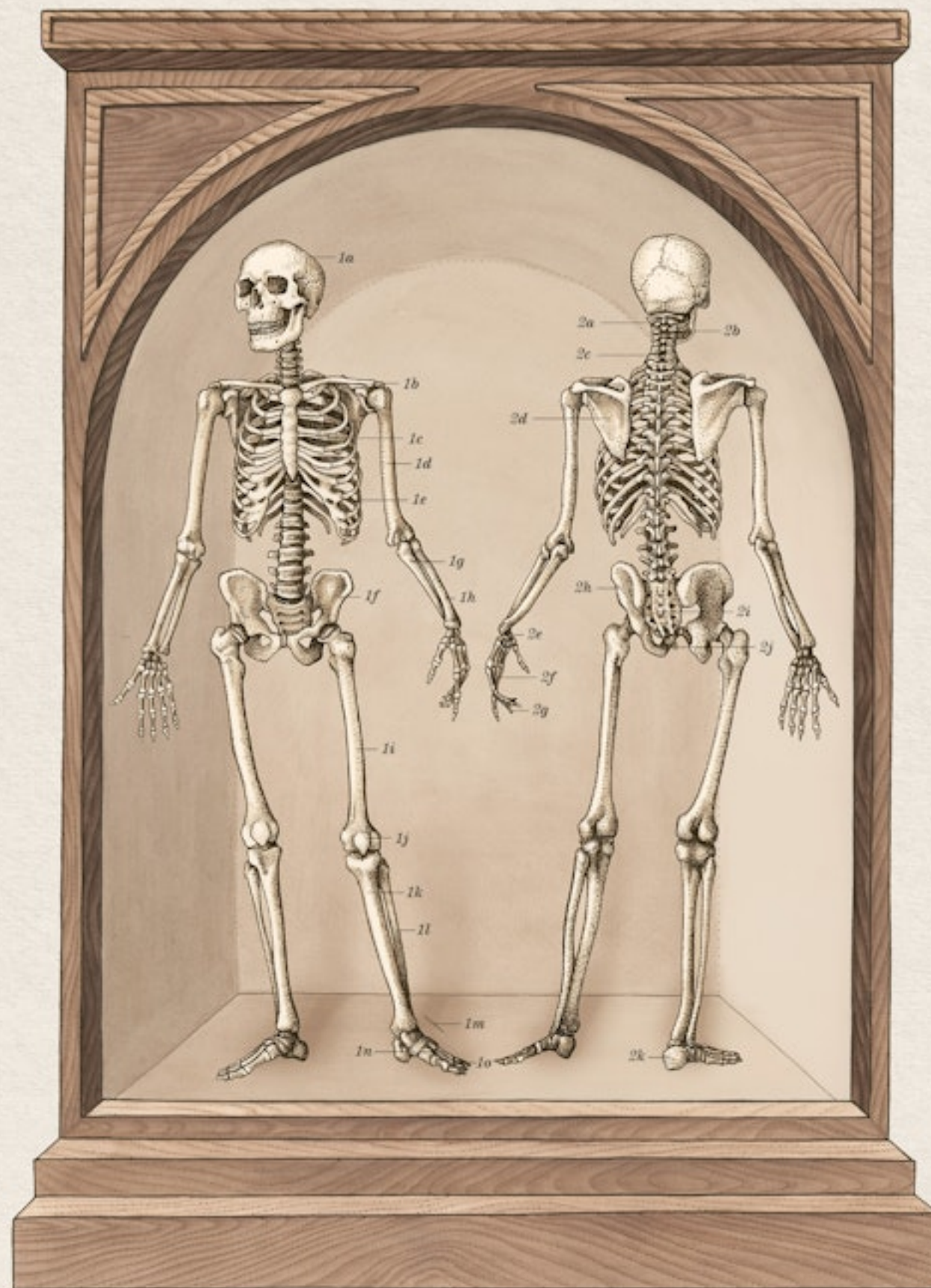- a) Cranium (skull bones)
- b) Clavicle (collar bone)
- c) Sternum (breast bone)
- d) Humerus (arm bone)
- e) Ribs
- f) Pelvis (hip bones)
- g) Ulna (inner forearm bone)
- h) Radius (outer forearm bone)
- i) Femur (thigh bone)

- j) Patella (knee cap)
- k) Tibia (inner leg bone)
- l) Fibula (outer leg bone)
- m) Tarsal bones (ankle and foot bones)
- n) Metatarsals (bones of the foot)
- o) Phalanges (toe bones)

### 2: Skeleton, seen from the back (posterior view)

- a) Atlas (1st spine bone)

- b) Axis (2nd spine bone)
- c) Vertebral column (spine or backbone)
- d) Scapula (shoulder blade)
- e) Carpal bones (wrist bones)
- f) Metacarpals (hand bones)
- g) Phalanges (finger bones)
- h) Ilium (one of the pelvis bones)
- i) Sacrum (fused bones at base of spine)
- j) Coccyx (tail bone)
- k) Calcaneus (heel bone)





# Bones

Bones come in all shapes and sizes, but can be roughly grouped into five types: long, short, flat, sesamoid and irregular. Long bones, such as those in the arm or thigh, usually support the body's weight. Short bones, found in the wrist and ankle, are roughly cube-shaped and support the joints. Flat bones, like the bones of the skull, are thin and curved, and protect the body's organs. Sesamoid bones (named after their resemblance to sesame seeds), such as the patella in the knee, are small, round bones sometimes found at joints. All other kinds are described as irregular bones, which have complex shapes designed for specific jobs, for instance the bones of the vertebral column.

All bones are made from a substance called mineralised collagen: a mixture of calcium minerals (which make bones sturdy) and collagen (which makes bone a little springy). This combination ensures bones are strong while preventing them from snapping under pressure. In fact it is thought that, when comparing weight-for-weight, bone is around four times stronger than concrete and more resilient than a steel bar.

For hundreds of years, scientists thought bones were dry and lifeless, but today we know they are constantly growing and responding to the environment around them. We are born with over 300 bones, but as we age, some of these fuse together to make the 206 bones of the adult skeleton. Bones have the ability to repair themselves, too. A rich blood supply ensures nutrients are directed straight to the damaged area of any bone, and most fractures take just six weeks to heal. Bones also respond to our lifestyle, specifically to exercise, with more bone produced following increased movement. For example, tennis players often have stronger bones in their serving arm compared to their other arm. In contrast, inactivity after long periods of illness (or in astronauts returning from space) makes bones weaker and more likely to fracture. This shows that the best way to keep strong, healthy bones is to exercise regularly.

## Key to plate

### 1: Vertebra

**a)** Single vertebra (viewed from above): Vertebrae are irregularly-shaped bones whose complex shape provides support for the upper body. The spinal cord runs through a hole in the middle of the vertebra called the vertebral foramen.

**b)** Vertebral column and ribs (from behind): The vertebral column, or spine, is made up of 33 individual vertebrae. Ribs articulate with 12 of them to form 24 ribs in total.

### 2: Bones of the knee region

**a)** Femur

**b)** Tibia

**c)** Patella: This is an example of a sesamoid bone; a bone inside a tendon that resembles a sesame seed.

**d)** Fibula

### 3: Bones of the right foot, seen from above (superior view)

The 26 bones of the foot have a variety of shapes and sizes. The tarsal bones that make up the ankle region are short bones that fit together.

### 4: Sternum, seen from the front (anterior view)

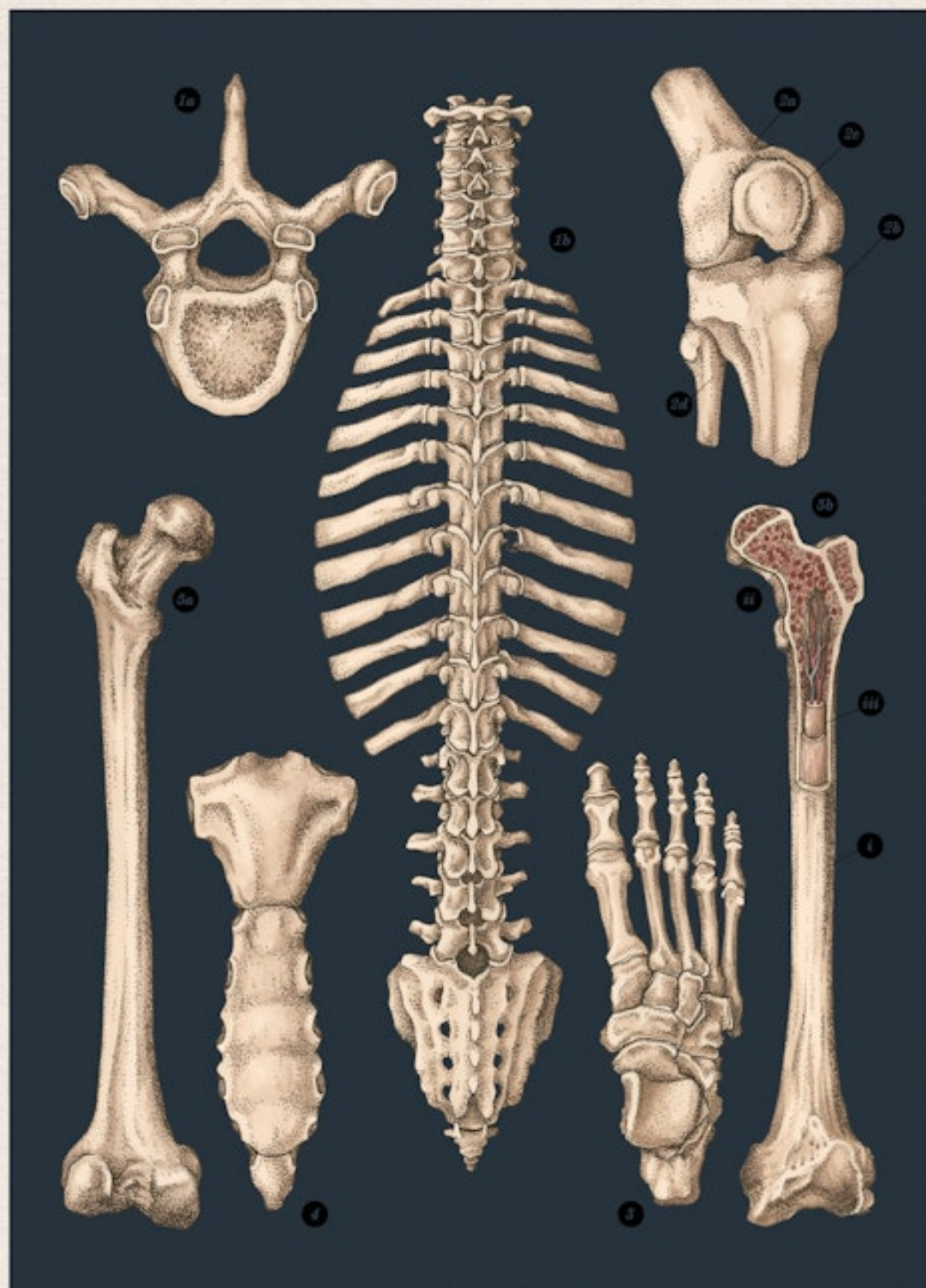
The sternum, or breastbone, is a flat bone at the front of the ribcage. Looking a bit like a tie, or an upside-down sword, it joins the cartilage of the ribs on both sides of the chest together and helps to protect the delicate heart and lungs underneath it.

### 5: Femur, seen from the front (anterior view)

**a)** Seen from the back (posterior view):

The rounded ball at the top of this long bone is the femoral head, which forms part of the hip joint.

**b)** Cross-section of femur seen from the front: The long bone of the femur contains a long shaft between the two rounded ends. The outer surface of the shaft is made from compact bone (**i**), making the femur strong. Air-filled spongy or cancellous bone (**ii**) found at the rounded ends makes the bones lighter. A medullary cavity (**iii**) runs through the shaft, containing blood vessels, nerves and bone marrow, where blood cells are made.





# The Skull

Underneath the skin and muscles of our head lies the skull, a protective home for the brain and sensory organs (the eyes, ears, nose and tongue). Although it appears to be a single bone, it is in fact formed of 22 individual bones, most of which are fused together at non-moveable joints known as sutures. The top part, or vault, is formed of eight bones and acts like a helmet, shielding the delicate brain inside from injury. The other 14 bones provide shape for the face and jaw. Only one of these, the mandible or jaw-bone, can move. This bone is joined to the skull by a hinge joint, letting us open and close the jaw during chewing and talking.

Most of the bones in the face are not solid, but have air-filled spaces within them called sinuses. These reduce the overall weight of the skull and add a deeper, clearer sound to our voices during speech, by allowing air to vibrate within them. In addition to sinuses, there are a number of holes running right through the skull bones, known as foramina. These let the brain connect with other parts of the body via nerves, and allow blood vessels to pass to and from the brain and face. The largest hole in the entire skull is at its base and is the foramen magnum, meaning 'great hole'. This large, oval shaped space is where the brain joins to the spinal cord.

You might notice that some facial features are missing from the skull – there are no ears or nose visible. This is because the shape of the outer nose and ear is made from cartilage, a material which is softer, and decays more rapidly, than bone.

After death, a skull may provide many clues about who it belonged to. We can ascertain age, gender and ethnicity by studying the skull's size and features, and (as with other bones) it is possible to see what diseases a person may have suffered from or even where they may have lived. Scientists known as palaeoanthropologists can study bones to discover facts about ancient cultures, while forensic osteologists study bones to uncover vital clues about the cause of death in criminal cases.

## Key to plate

### 1: Adult skull

a) From the front.

b) From the back: The sagittal (i) and lambdoid (ii) sutures can be seen, that join the parietal (iii) and occipital (iv) skull bones together.

c) From the base (without jaw).

The large central hole in the base of the skull is called the foramen magnum. This is the point where the spinal cord passes out of the skull to travel down the vertebral column.

d) From the side: The coronal (i), squamous (ii) and lambdoid (iii) sutures, which join the frontal (iv),

parietal (v), temporal (vi) and occipital (vii) skull bones together. e) Cross-section from the side. The space inside the skull where the brain sits is called the cranial fossa.

### 2: Newborn skull

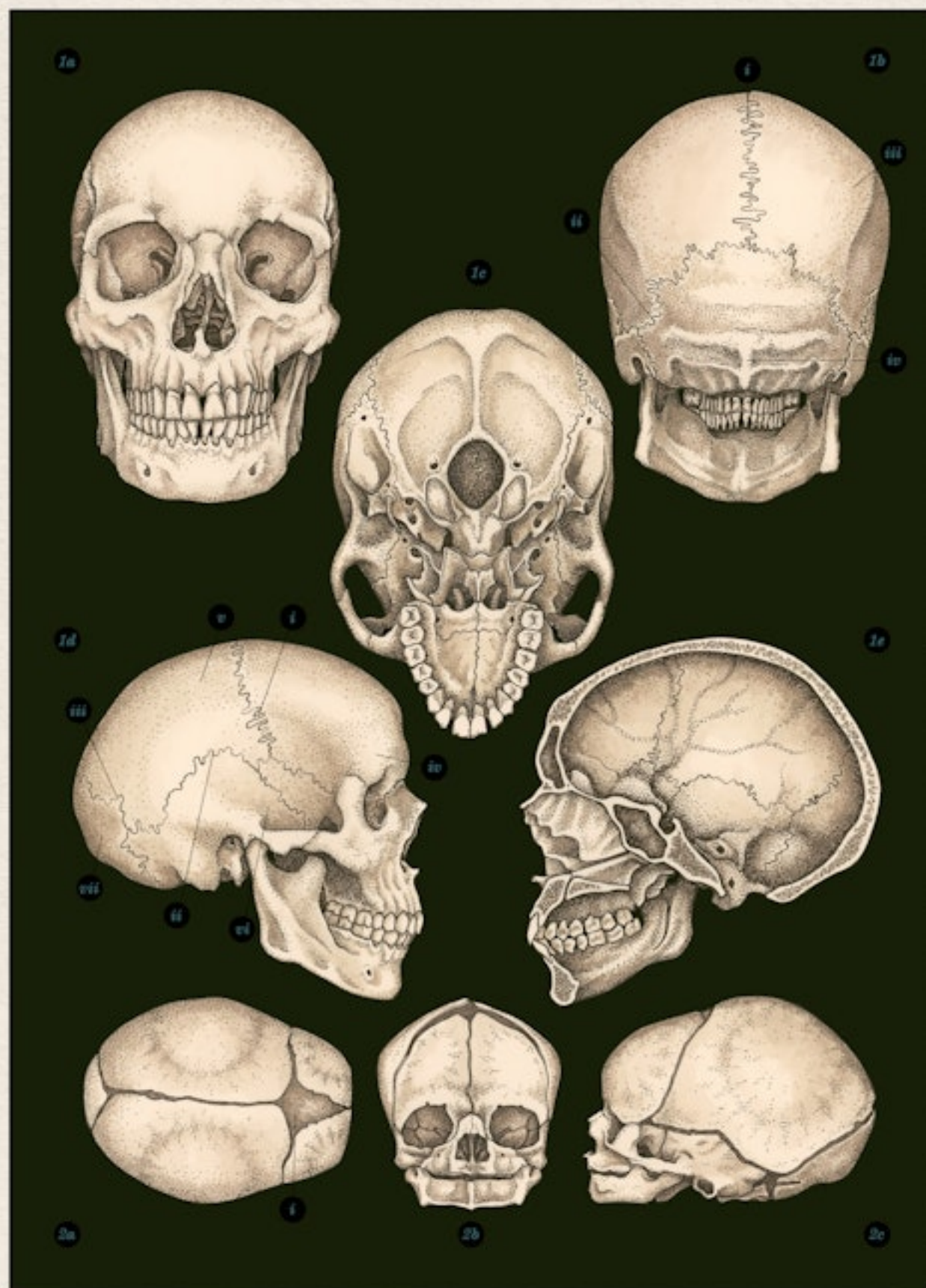
Although the bones of an adult skull are fused together and cannot move, in babies, these joints have not yet hardened. Instead, the sutures are formed from a much more flexible material, creating 'soft spots' or fontanelles in a baby's skull. Babies' brains grow rapidly as they develop,

from only about 350g at birth to nearly 600g in the first three months – about half the size of an adult brain. Fontanelles mean that the skull can easily cope with this rapid growth.

a) From the top: The diamond-shaped area is known as the fontanelle (i), or 'soft spot' of a baby's skull.

b) From the front: Infant skulls display more prominent forehead, orbits and a smaller jaw than the typical adult skull.

c) From the side: The prominent forehead and shape of the small jaw is noticeable.





# Joints

Joints, or articulations, are the points where two or more bones link together in the skeleton. There are over 300 joints in the body, with every bone connected to at least one other (except in the case of the hyoid bone in the throat). Although joints are often thought of as the moveable parts of the skeleton, there are actually three different types; some moveable, and others completely rigid.

Fibrous or immovable joints serve the important function of holding bones together for stability. For example, the bones of the adult skull come together at fibrous joints called sutures. Fibrous joints also hold teeth securely in place in their bony sockets.

Slightly more flexible than these is a group known as cartilaginous joints, where a layer of cartilage (a tissue softer than bone) sits between the bones and joins them together. These exist between the ribs and the breastbone, between the two sides of the pelvis and between the vertebrae of the spine. As these joints allow for a little movement, the bones can shift position slightly when needed. For instance, the joints in the pelvis become more flexible during pregnancy, enabling women to give birth more easily.

By far the most common type of joints are the moveable, or synovial, joints, including the hip, knee, shoulder and elbow. Although each joint has a unique shape, the basic structure is the same in all synovial joints. The ends of the bones are covered in a layer of hyaline cartilage, which helps to reduce friction as the bones slide past each other. The bones are held together by tough bands of tissue called ligaments, while a strong but flexible capsule wraps around the joint like a cuff to help keep it together. These joints also contain a slippery liquid called synovial fluid, which keeps them well lubricated, a bit like using oil to help a metal hinge move more easily. Have you ever heard your knee joints 'popping' when you stand up quickly or your knuckles 'cracking'? This noise might sound strange but it is just the sound of air bubbles in the synovial fluid bursting and is completely harmless.

## Key to plate

### 1: Pivot joint

In pivot joints, one bone rotates around another. A good example is the joint between the atlas and the axis in the vertebral column. It is used to turn our head from side to side.

### 2: Ball and socket joint

This joint gets its name from the 'ball' of one bone, usually a long bone, fitting into a corresponding 'socket' on the adjoining bone. It allows movements in lots of different directions (bending, rotation, etc.). Some good examples are the shoulder and hip joints.

### 3: Hinge joint

Hinge joints allow movement in one direction only and act just like hinges on doors to allow bending but not rotation. Major hinge joints of the body are at the elbows, knees and ankle joints.

### 4: Condyloid joint

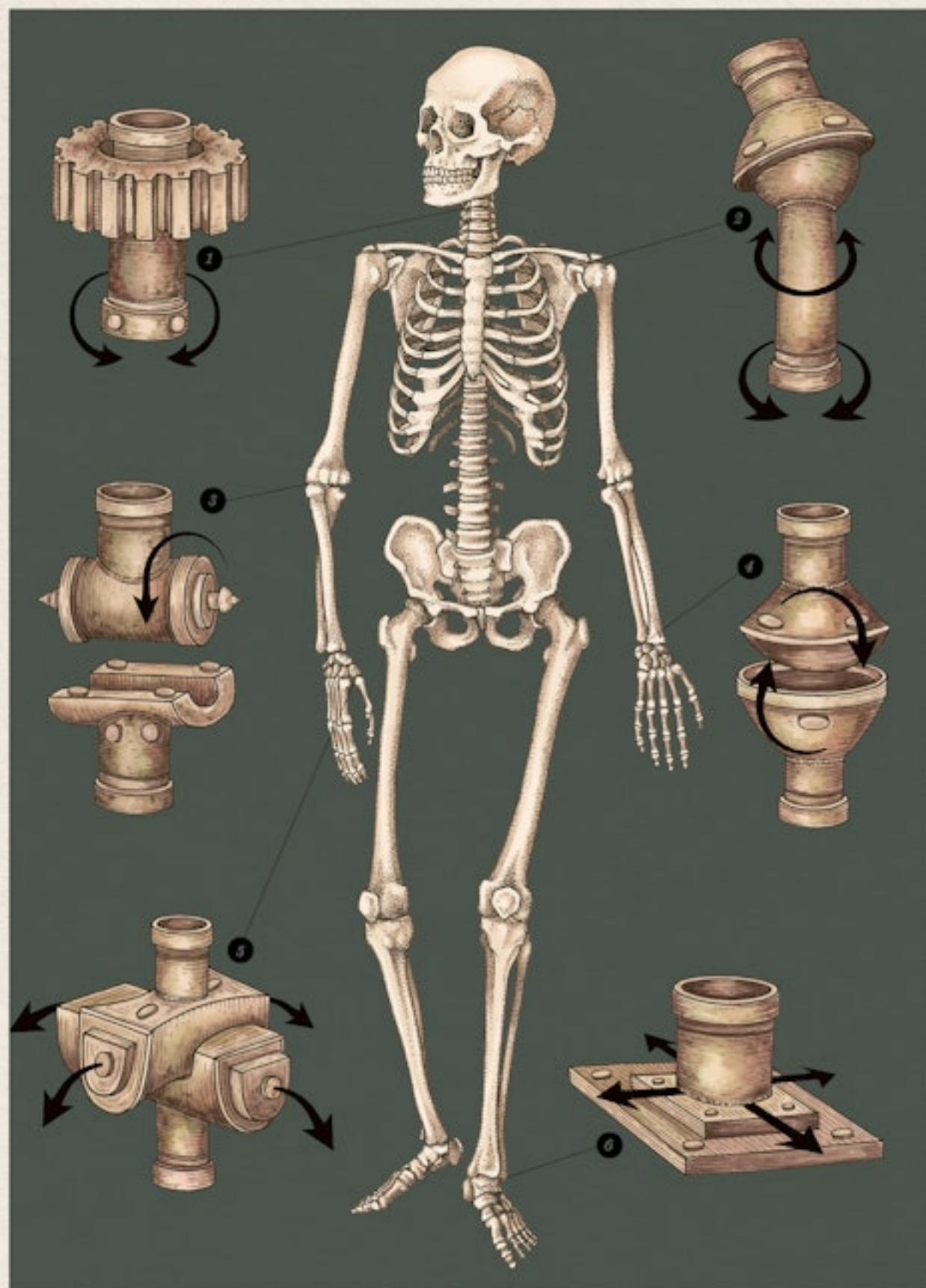
These are found where one bone is rounded and fits into a shallow depression on its neighbouring bone. Condyloid joints, also known as ellipsoidal joints, allow movements in many directions, such as the movements of the wrist.

### 5: Saddle joint

Resembling a saddle on top of another bone, these joints allow side-to-side and bending movement, but no rotation. They include the joint between the carpals and metacarpals of the thumb.

### 6: Planar joint

Also called gliding joints, these occur where bones lie flat against each other. They allow bones to slide from side to side or up and down. Planar joints are found between the bones in the wrist and ankle regions.





# Connective Tissues

Bones and muscles are not the only tissues in the skeletal system. Joining bones to bones, and attaching bones to muscles, are a number of connective tissues – tendons, ligaments and cartilage – which link, support and protect the entire skeleton.

Tendons are thick straps of tissue joining muscle to bone. When a muscle contracts, it shortens, pulling on the tendon so that it moves the bone. Tendons are made from a protein called collagen, with long fibres side by side in a structure resembling a thick, strong, stretchy rope.

Ligaments have a similar rope-like structure and are also made from collagen. However, instead of connecting muscle to bone, ligaments connect bone to bone, helping to keep joints stable. As a general rule, the worse the bones of the joint fit together, the better the ligaments at the joint need to be. For example, the bones of the knees do not slot together very well, so the knee joint has several ligaments inside and outside the joint to help provide stability.

Cartilage is a soft, flexible substance found all over the body in three different types. Hyaline, or articulating, cartilage is found on the surface of bones in moveable joints, where it acts as a shock absorber and reduces friction between bones. While tendons and ligaments are strong when they are pulled, cartilage is strongest when it is pressed, and so is well-suited to absorbing the forces occurring during movement such as jumping, running and playing sport. Another type of cartilage, fibrocartilage, is found in soft, squashy discs between the vertebrae of the spine and also between the bones of the knee joint. Lastly, elastic cartilage, a specialised bouncy tissue, creates the shape of the outer ear, allowing it to spring back into shape when bent.

## Key to plate

**1:** Knee joint and leg (without muscles), seen from the front and side (anterior and lateral view)

**a)** Quadriceps tendon. This joins the quadriceps muscle to the tibia (shin bone) and holds the patella.

**b)** Patella (knee cap)

**c)** Fibular collateral ligament. This connects the femur to the fibula.

**d)** Cartilage. This sits on the surface of bones where they meet other bones in the skeleton. Its role is to reduce friction as the bones rub together.

**e)** The anterior and posterior cruciate ligaments. These sit inside the knee joint and join the femur and tibia together.

**f)** The patellar ligament. This joins the patella to the tibia.

**g)** Ligaments of the ankle joint. These help to hold the ankle bones together for stability.

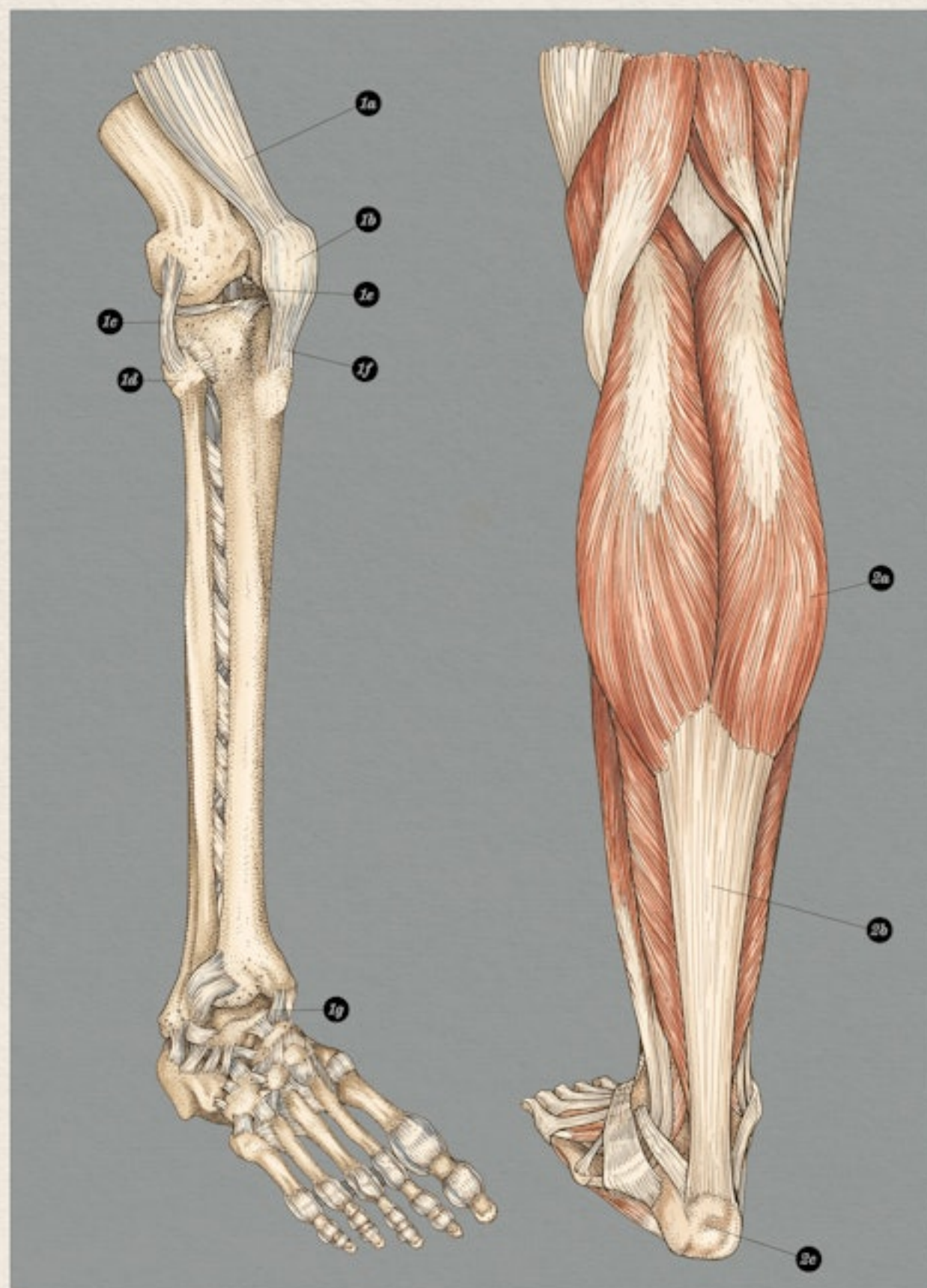
**2:** Knee joint and leg (with muscles), seen from the back (posterior view)

**a)** Gastrocnemius muscle (calf muscle)

**b)** Achilles tendon. The largest and strongest tendon in the body, which can easily be felt at the back of the heel. It joins the gastrocnemius muscle (calf muscle) to the heel bone. When the muscle contracts, it lifts the heel bone upwards, to pull us up onto our

toes. The tendon is named after the ancient Greek warrior Achilles, who was said to be immortal after being dipped in the River Styx as a baby. The only part of him untouched by the water was his heel, as this was where his mother held him. Achilles was later killed after being shot in the heel with an arrow – his only weak spot (and the origin of the expression 'Achilles' heel'). The naming of the Achilles tendon calls to mind how vulnerable we are if this crucial tendon becomes injured.

**c)** Calcaneus (heel bone)





# The Muscular System

From the cautious first steps of a baby finding its way in the world, to the speed of an Olympic athlete or the grace of a ballet dancer, the muscular system is responsible for producing every possible kind of movement.

Found throughout the body in three types – skeletal, cardiac and smooth – all muscle tissue shares one important feature: the ability to contract, or shorten, making part of the body move. In skeletal muscle, contractions pull on the bones they attach to, moving them into a new position. Because these muscles can only pull in one direction, they usually work in pairs. So after one muscle contracts to bend a joint, a corresponding muscle contracts to straighten it out again. For example, when the biceps muscle in your upper arm contracts, it pulls on tendons connecting to your forearm, raising your hand and wrist upwards. To lower your forearm again, the biceps relaxes and the triceps muscle on the underside of your arm contracts instead. Skeletal muscle gives the body its shape, and is thought to account for around 40 per cent of an adult's total body weight.

As well as moving the skeleton, the muscular system has other key roles, from pumping blood around the body (cardiac muscle), to moving food through the digestive tract (smooth muscle), to communicating via facial expressions (skeletal muscle). Muscles even have a role to play in keeping us warm – in fact, muscle contractions produce around 70 per cent of our total body heat.

## Key to plate

### 1: Skeletal muscles, seen from the back (posterior view)

There are over 600 named skeletal muscles in the body. Their names follow simple rules based on the action, shape, size or location of the muscle. Flexor and extensor are commonly used prefixes, which identify their function as flexors (for bending) or extensors (for straightening) at joints.

Scientific terms also relate to the comparative size of muscles such as maximus (large), minimus (small),

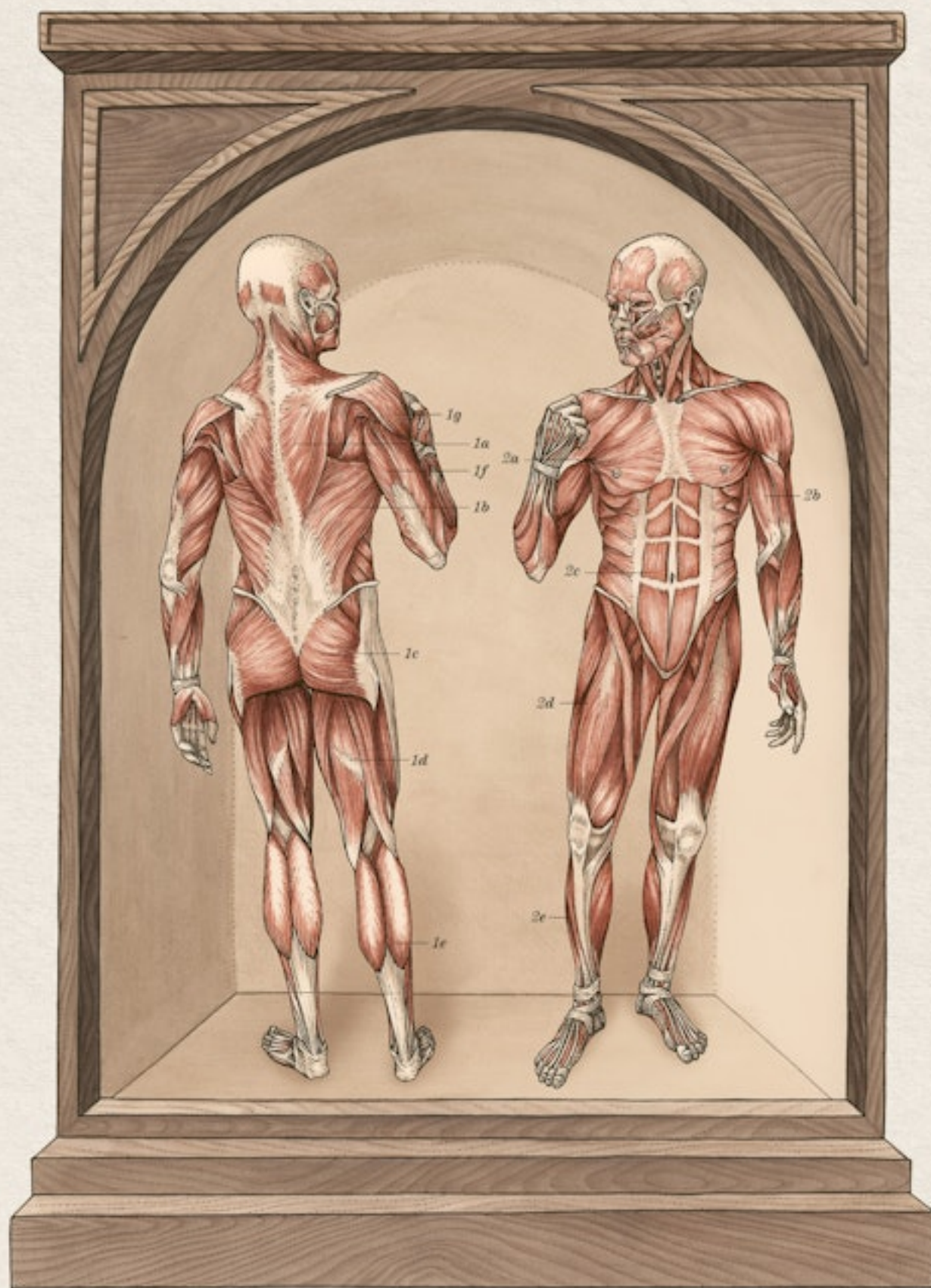
longus (long) and brevis (short). The word 'muscle' itself comes from the Latin for 'little mouse', suggested to be because the muscle belly (the central part that bulges) and tendon (that attaches it to the bone) resemble a mouse and its tail.

- a) Trapezius
- b) Latissimus dorsi
- c) Gluteus maximus
- d) Hamstrings (semitendinosus, semimembranosus and biceps femoris)
- e) Gastrocnemius

- f) Triceps brachii
- g) Deltoid

### 2: Skeletal muscles, seen from the front (anterior view)

- a) Pectoralis major
- b) Biceps brachii
- c) Rectus abdominus
- d) Quadriceps (rectus femoris, vastus lateralis, vastus medialis, vastus intermedius)
- e) Tibialis anterior





# Muscle Tissue

Muscle tissue is formed of thousands of long, thin cells called myocytes, which contract together to make a muscle change shape. Skeletal, cardiac and smooth muscle are all made of myocytes, but arranged in very different ways – some moved by involuntary (automatic) control and some by voluntary (conscious) control.

Skeletal muscle, which attaches to the body's skeleton, is formed of myocytes combined in long, thin strands called muscle fibres. These combine to give the shape of the 'belly' – the rounded part of the muscle you can see beneath the skin. Skeletal muscles are all under voluntary control, meaning we have to think in order to move them: electrical signals are sent from the brain, via the spinal cord, to nerves within the muscle. By contrast, cardiac and smooth muscles move automatically, without us ever having to think about them. This is known as involuntary control.

Cardiac muscle makes up the walls of the heart and is not found anywhere else in the body. Its role is to squeeze the heart's chambers in a steady rhythm, transporting blood all around the body. The regular squeezing occurs as electrical impulses travel through structures like wires within the muscle tissue itself.

Smooth muscle appears in the walls of blood vessels, parts of the urinary system and the digestive tract. It is activated via signals from the nervous system, and mostly controls the width of tubes or tracts, tightening or relaxing to control what's inside them. For instance, the squeezing motion known as peristalsis pushes food down the digestive tract, just like squeezing toothpaste out of a tube. Smooth muscle is also found in the walls of the bladder. In fact, the bladder has one of the only smooth muscles to be given its own name – the detrusor muscle. When you go to the toilet, the detrusor muscle squeezes to push urine out. Since the bladder is made from smooth muscles, this is not under voluntary control, but a special muscle valve stops the urine flowing out unless we tell it to. This lets us control where and when we empty our bladder.

## Key to plate

### 1: Cardiac muscle

**a)** Heart: Cardiac muscle makes up the walls of the heart and its contraction pumps blood around the heart and on to the lungs or the rest of the body.

**b)** Cardiac muscle structure: The microscopic visualisation of cardiac muscle reveals its structure. Cardiac muscle cells have a branched shape, striated (or striped) appearance and each cell contains a single nucleus. Cells are joined together at areas called intercalated discs, which help transmit the

electrical signal needed to contract the muscle.

### 2: Smooth muscle

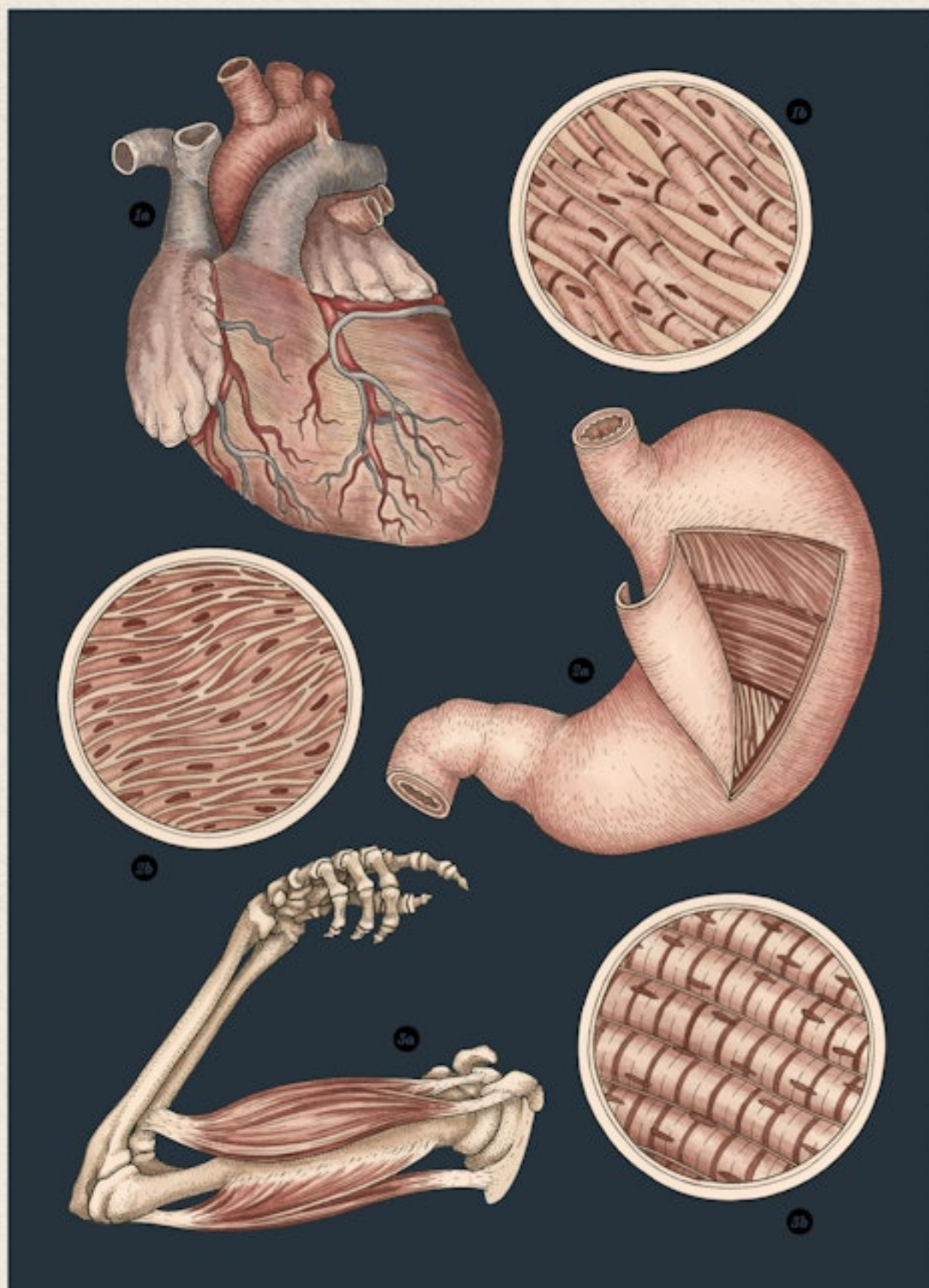
**a)** Stomach: The walls of the stomach are made from three layers of smooth muscle, each orientated in a different direction. These muscles move in a churning motion to mix the stomach contents effectively.

**b)** Smooth muscle structure: The microscopic structure of smooth muscle cells display long, thin cells, each with an individual nucleus, but no striations (stripes).

### 3: Skeletal muscle

**a)** Biceps brachii: All skeletal muscles have at least one origin (the point where the muscle originates from a bone) and insertion point (where it attaches to another bone). Biceps brachii has two origins, which explains its name (biceps means two heads). Contraction of biceps brachii leads to bending the upper limb at the elbow.

**b)** Skeletal muscle structure: The structure shows muscle cells in the form of muscle fibres, each with multiple nuclei. The muscle fibres are highly striated (striped).





# Muscles: The Hands

Most animals use their hands as supports when walking on 'all fours', a type of movement known as a quadrupedal gait. In humans, however, our upright walking position on two feet – a bipedal gait – has enabled our hands to develop into functional tools. In fact, our hands, and the incredible range of movements they can perform, are key to the skills that distinguish us from other species.

Our hands are used almost constantly, from the moment we wake until we fall asleep. We need them for eating, washing, carrying objects, as well as for communicating through hand gestures and body language. The intricate machinery of the hand also lets us perform more specialised, complicated movements such as playing a musical instrument, texting on a mobile phone, buttoning up a shirt or turning a key in a lock.

Interestingly, the fingers themselves do not contain any muscles. Instead, movements of the fingers, such as clenching and straightening, are caused by muscles in the forearm and hand. The tendons of these muscles travel along the length of the fingers to the tips, like long strings, carefully weaving past each other and enabling movements at the joints between the finger bones. Other small muscles within the palm of the hand produce finer movements of the fingers, needed for precise actions.

One of the key movements for the usefulness of our hands is the ability to oppose the thumb. This means we can move the thumb across the palm so that the tip of the thumb touches the tip of the little finger. In fact, the majority of hand actions we rely on every day would not be possible without our opposable thumbs.

## Key to plate

### 1: Bones of the left hand and wrist

The 27 bones are split into 14 phalanges, 5 metacarpal bones and 8 carpal bones, that fit together snugly like pieces of a jigsaw puzzle.

a) Phalanges

b) Metacarpal bones

c) Carpal bones

### 2: Soft tissues of the hand

For hand and finger movements to occur, there are many muscles in the forearm that send their long tendons down into the fingers. These tendons are held in place under little casings

called sheaths that help the tendons glide smoothly during movements. There are also many muscles in the palm of the hand that help with fine motor movements.

### 3: Power grip

This type of grip is useful for carrying objects, such as shopping bags or suitcases, or holding objects like a hammer or a baseball bat.

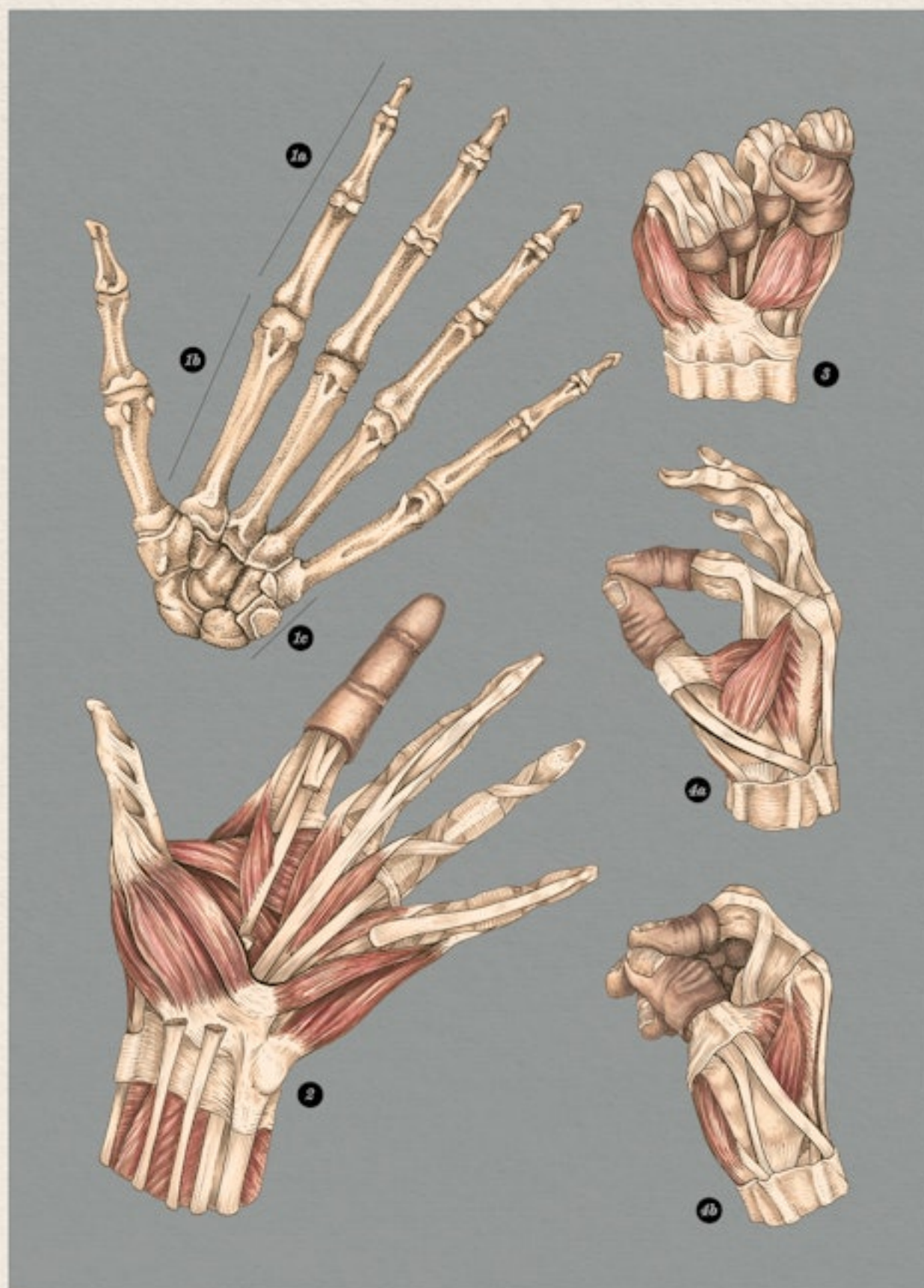
### 4: Precision grip

These types of grip are useful for picking up small objects and require

a high level of fine finger movement and accuracy.

a) Pincer grip: This delicate 'precision grip' joins the index finger and opposable thumb. It is a key grip for picking up objects.

b) Dynamic tripod grip: Often used for holding a pen, this precision grip uses the thumb, index and middle fingers for support and precision.





# Muscles: Facial Expression

You can often tell what emotion a person is feeling by the expression on their face. Are they happy, sad, angry or worried? How many times has a friend told you they are 'fine' but their expression tells a different story? Even though we communicate with each other by speaking, we also have an excellent ability to notice, understand and respond to non-spoken communication through body language, especially facial expressions.

Over 40 muscles lie under the skin of our face, which joins to the bones of the skull. They work together in many combinations, allowing us to produce approximately 10,000 different facial expressions, vital for our interaction and communication with others. Many of the facial muscles have a clear functional role, such as the muscles surrounding the eyes and mouth. For example, the orbicularis oculi muscle circles each eye and is used to close the eyelid, with extra contraction making the eyes 'screw up'. Orbicularis oris, the muscle around the mouth, is used to close and stick-out the lips and is therefore known as the 'kissing muscle'. Both the orbicularis muscles are flat, rounded structures and are very similar in shape; in fact their name comes from the Latin orbis meaning 'circular' or 'disc-shaped'. Other muscles can pull a part of the face up or down, such as the depressor anguli oris, which pulls the corners of the mouth downwards, creating a 'sad face' expression, or the levator palpebrae superioris, used to open the eyelid. The muscle used to convey surprise is the frontalis muscle on the forehead – it pulls the eyebrows upwards and wrinkles the forehead. We use many more muscles when we frown than when we smile. Real smiles of happiness also involve involuntary actions of the muscles around the eyes, not just the muscles surrounding the mouth. This means we can often tell the difference between a fake smile and a genuine one!

## Key to plate

### 1: Muscles of facial expression

- a) Frontalis
- b) Temporalis
- c) Orbicularis oculi
- d) Nasalis
- e) Orbicularis oris
- f) Levator labii superioris
- g) Zygomaticus major and minor
- h) Depressor anguli oris

### 1j) Platysma

### 1j) Mentalis

### 2: Kissing muscles

The orbicularis oris muscle closes and protrudes the lips as when kissing.

### 3: Muscles of smiling and winking

Zygomaticus major pulls the corners

of the mouth upwards when smiling.

In winking the orbicularis oculi

muscle contracts to close the eyelid.

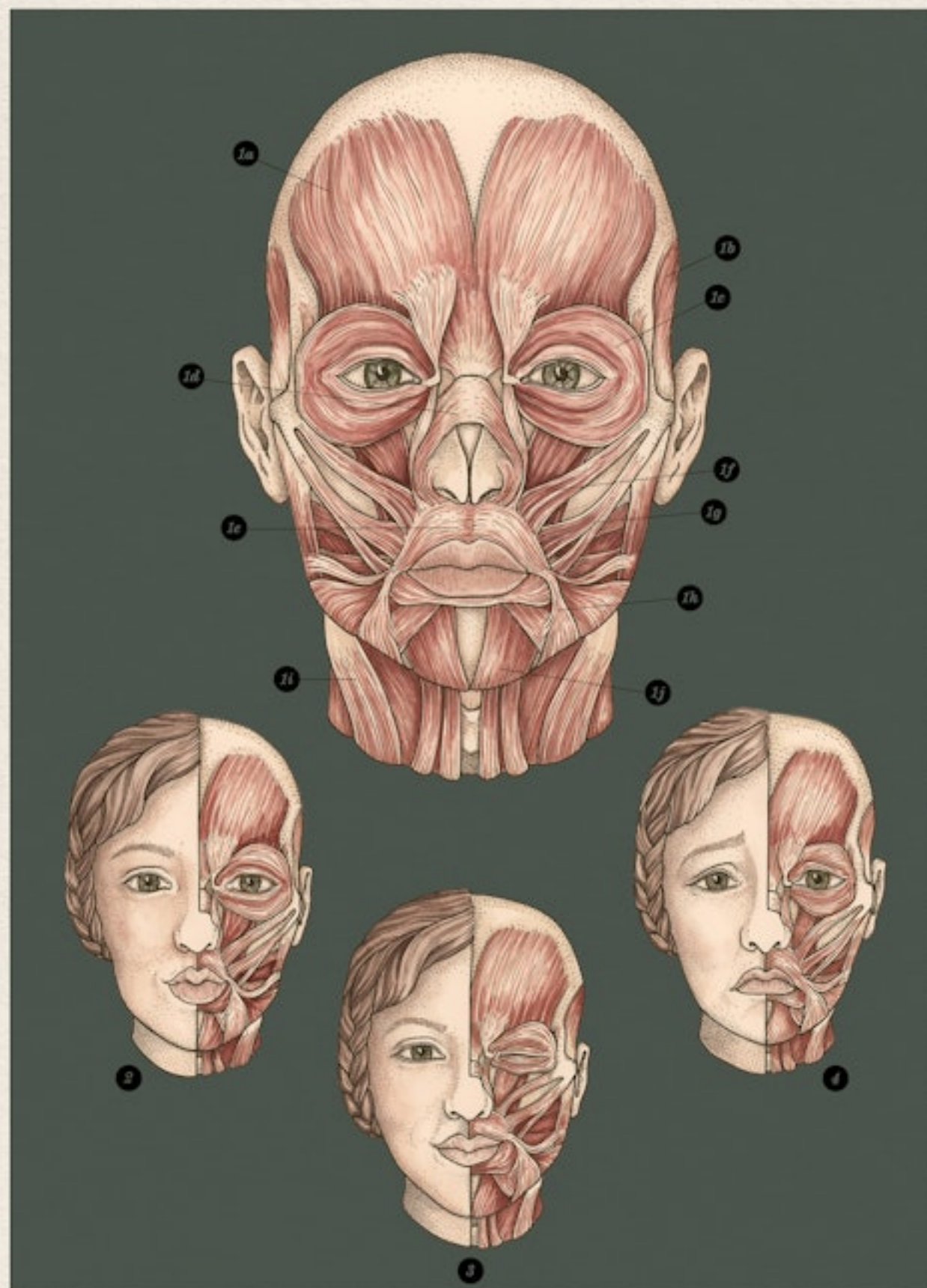
The orbicularis oculi also contract

involuntarily when you smile.

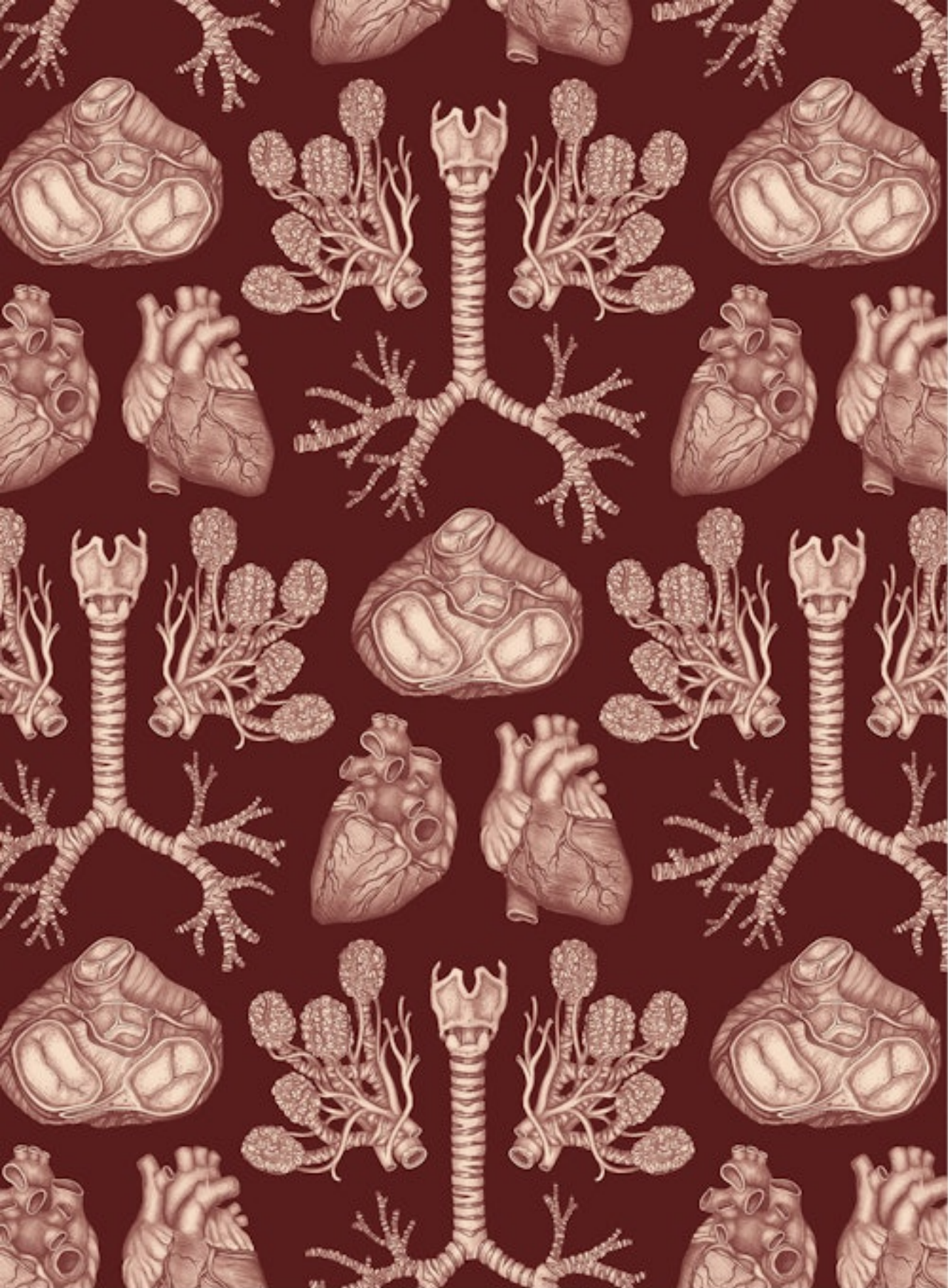### 4: Muscles of sadness

Depressor anguli oris pulls the corners

of the mouth downwards.



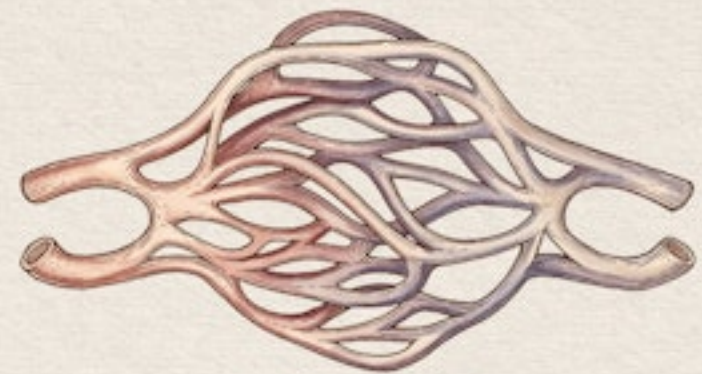



ANATOMICUM

*Gallery 2*

# The Cardiovascular & Respiratory Systems



*The Cardiovascular & Respiratory Systems*

*The Heart*

*Blood*

*The Respiratory Tract*

*The Lungs*



# The Cardiovascular & Respiratory Systems

Oxygen is a gas which makes up about 20 per cent of the air we breathe. This percentage can fluctuate between places, temperatures and altitudes, but getting enough of it into the body is essential to life. Just a few minutes without oxygen can be life threatening. That's because every cell in the body needs oxygen to convert into energy – a process known as respiration. When cells release energy, they also produce a gas called carbon dioxide, which the body needs to remove. Inhaling oxygen and exhaling carbon dioxide is the task of the respiratory system. This works closely together with the cardiovascular system, which pumps blood around the body to transport oxygen to each and every cell and simultaneously remove waste carbon dioxide.

To reach the body's cells, oxygen has to undertake a long journey through both systems. First, air is breathed in through the nose (and mouth) and travels through the trachea (windpipe) to reach the lungs. Here, oxygen from the air is transferred into the body's bloodstream and enters the cardiovascular system. The oxygenated blood then has to travel right round the body's vast network of blood vessels, powered onwards by the beating of the heart. On arrival at each cell, blood delivers oxygen and other nutrients, and carries away waste products, including carbon dioxide. After this exchange, deoxygenated blood travels back to the lungs and respiratory system, where carbon dioxide is passed back into the lungs and breathed out. This vital process continues even as we sleep, pumping over 14,000 litres of blood around the body every single day.

## Key to plate

### 1: Heart

### 2: Arterial system

The collection of blood vessels called arteries transporting blood away from the heart and to the body tissues

- a) Ascending aorta
- b) Subclavian artery
- c) Brachial artery
- d) Radial artery
- e) Ulnar artery
- f) Descending aorta

### g) Common iliac artery

### h) Femoral artery

### i) Popliteal artery

### j) Anterior tibial artery

### k) Common carotid artery

### 3: Venous system

The collection of blood vessels called veins transporting blood to the heart

- a) Superior vena cava
- b) Subclavian vein
- c) Basilic vein

### d) Medial cubital vein

### e) Cephalic vein

### f) Inferior vena cava

### g) Common iliac vein

### h) Femoral vein

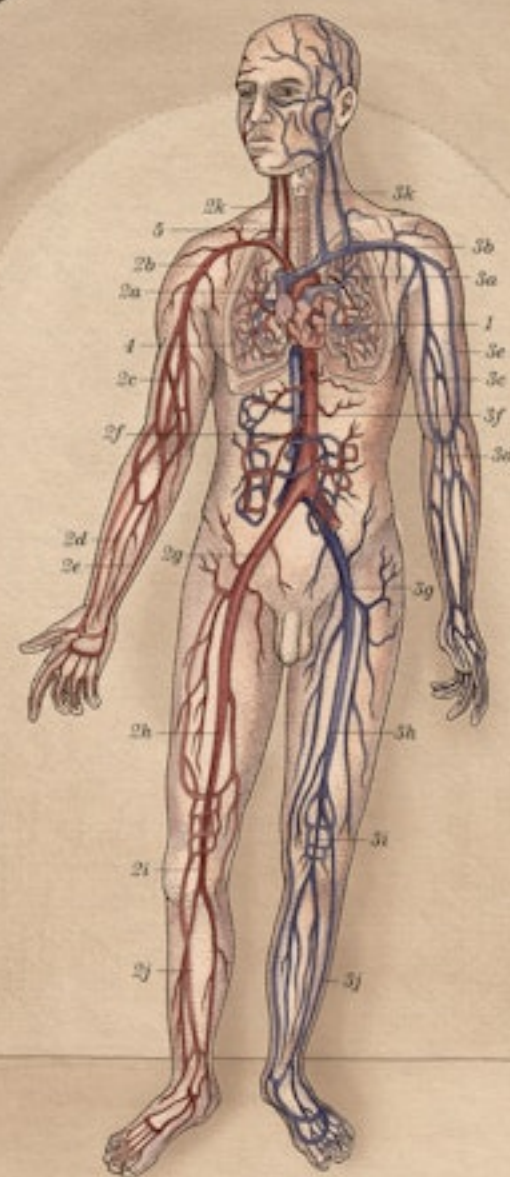
### i) Popliteal vein

### j) Anterior tibial vein

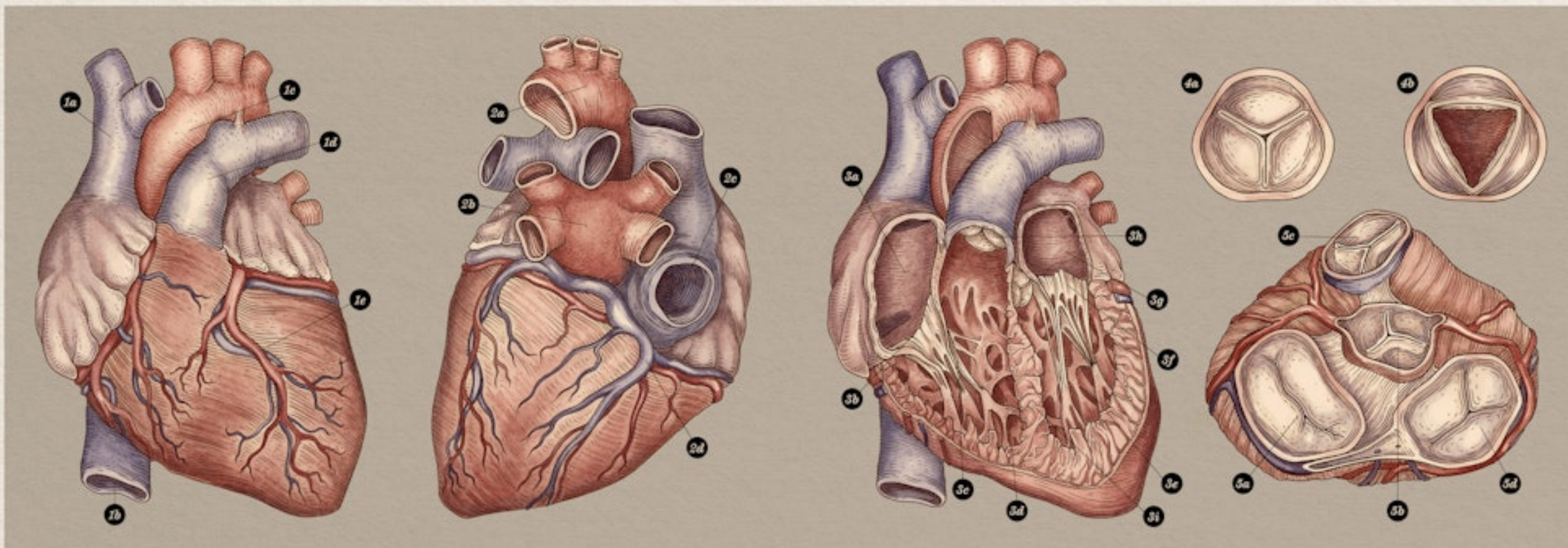
### k) Internal jugular vein

### 4: Lungs

### 5: Trachea (windpipe)







# The Heart

The hardest working muscle in the body is the heart, beating over 100,000 times every day of our lives to transport blood all the way around the body. Located under the ribcage and between the lungs, this organ is only about the size of a fist. It acts as a specialised pump – in fact, two pumps in one, each with a vital job to do. The right side of the heart pumps blood towards the lungs where it picks up oxygen. Oxygen-filled blood returns to the heart, where the left side pumps it on to the rest of the body. A thick wall called the septum divides the right and left sides, and keeps the blood in each 'pump' separate. Although both sides are similar in appearance, the left side is thicker and stronger as it has to push blood further around the body against high pressure.

The pumping action of the heart is produced by cardiac muscle in its walls, which contracts (squeezes) to push blood between one part of the organ and another. The four areas, or chambers, within the heart are split into two ventricles at the bottom and two atria at the top. With each heartbeat, the two atria contract first, pushing the blood inside them down into the ventricles. Then the ventricles contract, pushing the blood out of the heart and on to other parts of the body. After contracting, the heart muscle relaxes, allowing the chambers to refill with blood before the next contraction. One complete cycle of this pattern, or heartbeat, takes less than a second to occur.

It is crucial that blood only flows in one direction in the heart. To control this, special valves exist between the ventricles and atria and the blood vessels entering and exiting the heart. These act like trapdoors, letting blood flow through one way, but closing tightly to stop it from flowing backwards. These valves slamming shut make the rhythmic 'lub-dub' sounds of the heart beating.

## Key to plate

### 1: Heart, seen from the front (anterior view)

- a) Superior vena cava
- b) Inferior vena cava
- c) Ascending aorta (to body)
- d) Pulmonary trunk (to lungs)
- e) Cardiac blood vessels supplying the wall of the heart

### 2: Heart, seen from behind (posterior view)

- a) Arch of aorta
- b) Left atrium
- c) Entrance to right atrium via inferior vena cava

### 3: Heart, internal structure, from the front (anterior view)

- a) Right atrium
- b) Tricuspid valve
- c) Chordae tendineae (heart strings)
- d) Right ventricle
- e) Left ventricle
- f) Mitral (bicuspid) valve
- g) Left atrium
- h) Pulmonary valve
- i) Interventricular septum

### 4: Heart valves

Valves between the atria and ventricles, and ventricles and blood vessels, stop blood flowing backwards.

- a) Closed
- b) Open

### 5: Heart, with view of the valves, from above (superior view)

- a) Mitral (bicuspid) valve
- b) Aortic valve
- c) Pulmonary valve
- d) Tricuspid valve



# Blood

Blood is made up of billions of cells, all floating in a liquid called plasma – a watery mix of proteins, salts, nutrients and hormones. Around 99 per cent of blood cells are red. They contain a red pigment called haemoglobin which binds oxygen molecules to the cell so they can be carried all over the body. By contrast, white blood cells only make up 0.2 per cent of blood cells. They patrol the body like an army, attacking infections and removing damaged cells. The rest of the cells in blood are platelets (0.08 per cent), which help stop bleeding around cuts. Platelets clot the blood, making it thick and sticky to form a protective scab over the wound site.

A huge network of tubes called blood vessels lets blood travel to every part of our body, from our heads to our toes. Laid end-to-end, this vascular network would measure over 120,000 kilometres – long enough to circle the globe three times. Within this network, arteries carry blood away from the heart, veins carry blood towards the heart and capillaries join the two together.

All blood vessels have walls made of smooth muscle. The thickest walls belong to arteries, which must be strong enough to carry high-pressure blood away from the heart. As they move further from the heart, the arteries divide into arterioles, becoming smaller and smaller like the branches of a tree. When they reach the body's tissues they become the narrowest type of blood vessel: capillaries. The walls of capillaries are just one cell layer thick, enabling oxygen and carbon dioxide to easily pass between the cells and the blood flow. Once blood has travelled through the capillary, it flows into tiny veins called venules, which get bigger as they get closer to the heart. Veins have much thinner walls than arteries, because the blood they transport is not travelling with so much force. Valves within them ensure blood only flows in one direction, and never flows backwards. This is especially important in the lower limbs, where deoxygenated blood from the feet needs to be pumped upwards, against gravity, back to the heart.

## Key to plate

### 1: Artery

These thick-walled tubes transport blood away from the heart. They branch into smaller arterioles before joining capillaries. The biggest artery in the body is the aorta, which is 2–3cm wide and 30cm long in adults. It runs directly from the heart into the chest and abdomen.

### 2: Capillary bed

A collection of tiny blood vessels called capillaries form the capillary bed, where gas and nutrient exchange takes place.

### 3: Vein

These muscular tubes have thinner, stretchier walls than arteries and are much wider. They contain valves that stop the backflow of blood as it makes its journey back to the heart.

### 4: Blood composition

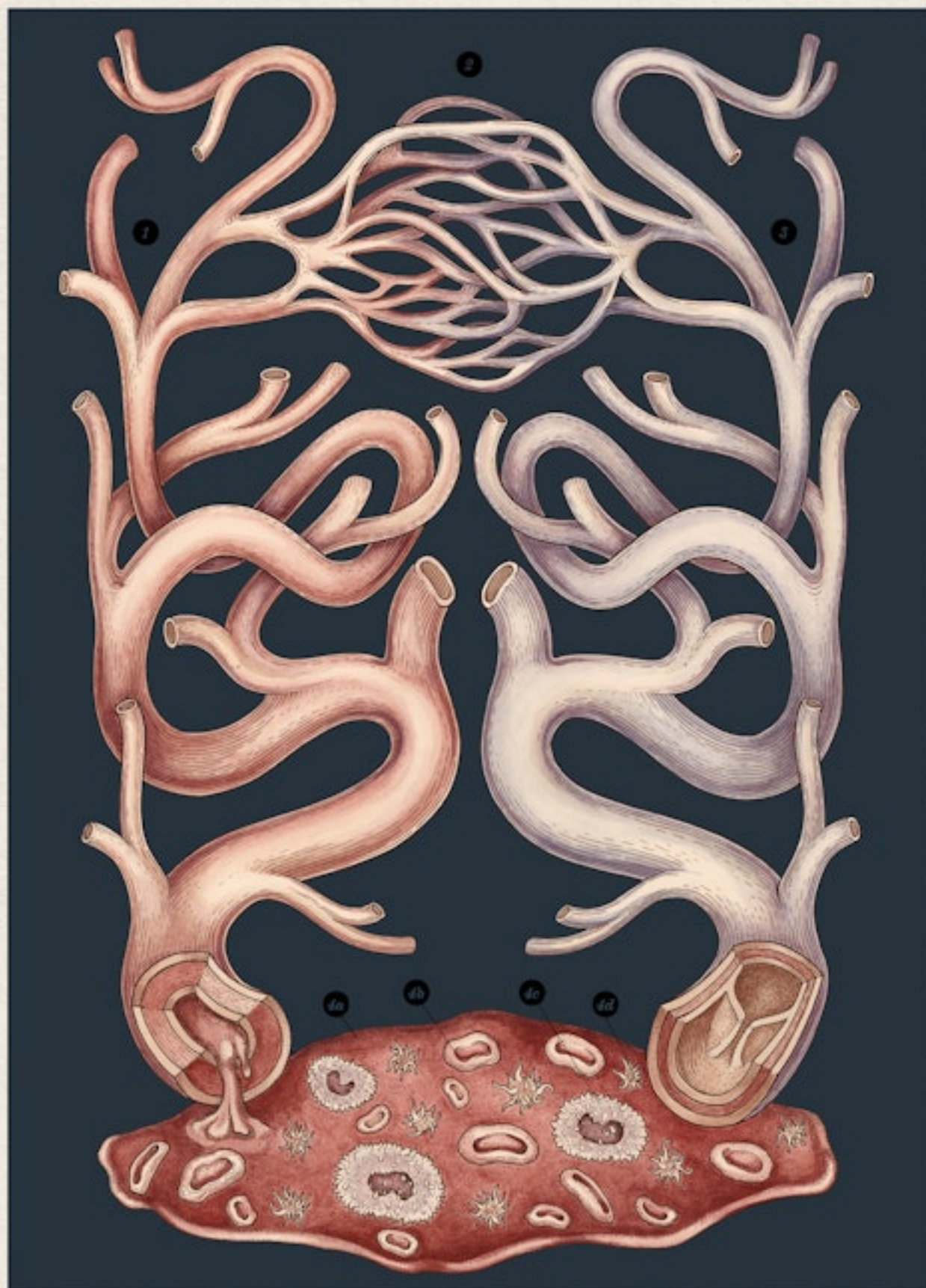
**a) Plasma:** This is a watery mixture of hormones and nutrients that makes blood flowable.

**b) Red blood cells:** These flat, disc-shaped cells carry oxygen around the body by binding it to the pigment haemoglobin, which gives blood

its red colour. Red blood cells are constantly renewed from the bone marrow, only lasting about 120 days in the body before being broken down and removed by the spleen.

**c) White blood cells:** These are part of the immune system and help the body to fight infection (see page 78).

**d) Platelets:** These are tiny cells which rush to wounds and form plugs, or scabs, to stop blood escaping the body.





# The Respiratory Tract

For the lungs to receive oxygen, air must find its way into the body. This journey begins at the nostrils: two holes in the nose lined with hundreds of little hairs. As air is breathed in, nasal hairs act like filters, trapping dirt and dust particles to stop them entering the lungs. Once air has passed through the nostrils, it enters the nasal cavity behind the nose, where sticky mucus traps any remaining dust.

From the nasal cavity, air travels through the pharynx (throat) to the larynx (voice box) where sound is produced during speech. The larynx contains two small flaps called vocal cords which vibrate when air is passed through them. The vocal cords open and close to alter the sounds made when talking, shouting or singing. Although the mouth and lips form most of the different sounds made during speaking, the larynx is responsible for the volume and pitch of the voice.

After air flows through the larynx, it enters the trachea, or windpipe. The trachea contains rings of cartilage, giving it a ridged appearance and making sure that it is held open to give a clear, open pathway for air to reach the lungs. At its base, the trachea branches into the bronchi, the two smaller airways that direct air into the lungs.

A major flaw in the human body's design is that food and air both travel along some common routes – the mouth and the throat. When food or drink enters through the mouth, it is normally directed towards the stomach using a clever trap door device called the epiglottis. However, if objects enter the windpipe instead, you can start to choke. Coughing – forcing air from the lungs – will usually dislodge an object, but if not removed it can stop air entering the lungs and even cause death.

## Key to plate

### 1: Upper respiratory tract, cross-section

- a) Nostrils
- b) Nasal cavity
- c) Pharynx (throat)
- d) Larynx (voice box)
- e) Vocal cords
- f) Sphenoid air sinus

### 2: Vocal cords, seen from above (superior view)

- a) Open position: The vocal cords are open during normal breathing, letting air pass through easily.
- b) Closed position: The cords close together, allowing a small gap for air to pass through, creating a noise.

The tone and volume of our voice is changed depending on the position of the vocal cords.

### 3: The larynx, seen from the front (anterior view)

- a) Hyoid bone: The only bone in the body not attached to another bone; instead it is attached to other structures by membranes.
- b) Thyroid cartilage: This looks like a shield and forms the 'Adam's apple', the protrusion in the neck, especially prominent in males.
- c) Cricoid cartilage: This is joined to the trachea by a membrane.
- d) Trachea: Also known as the windpipe, it is held in the shape of an open tube by a series of C-shaped cartilage rings.

### 4: The larynx, cross-section, seen from behind (posterior view)

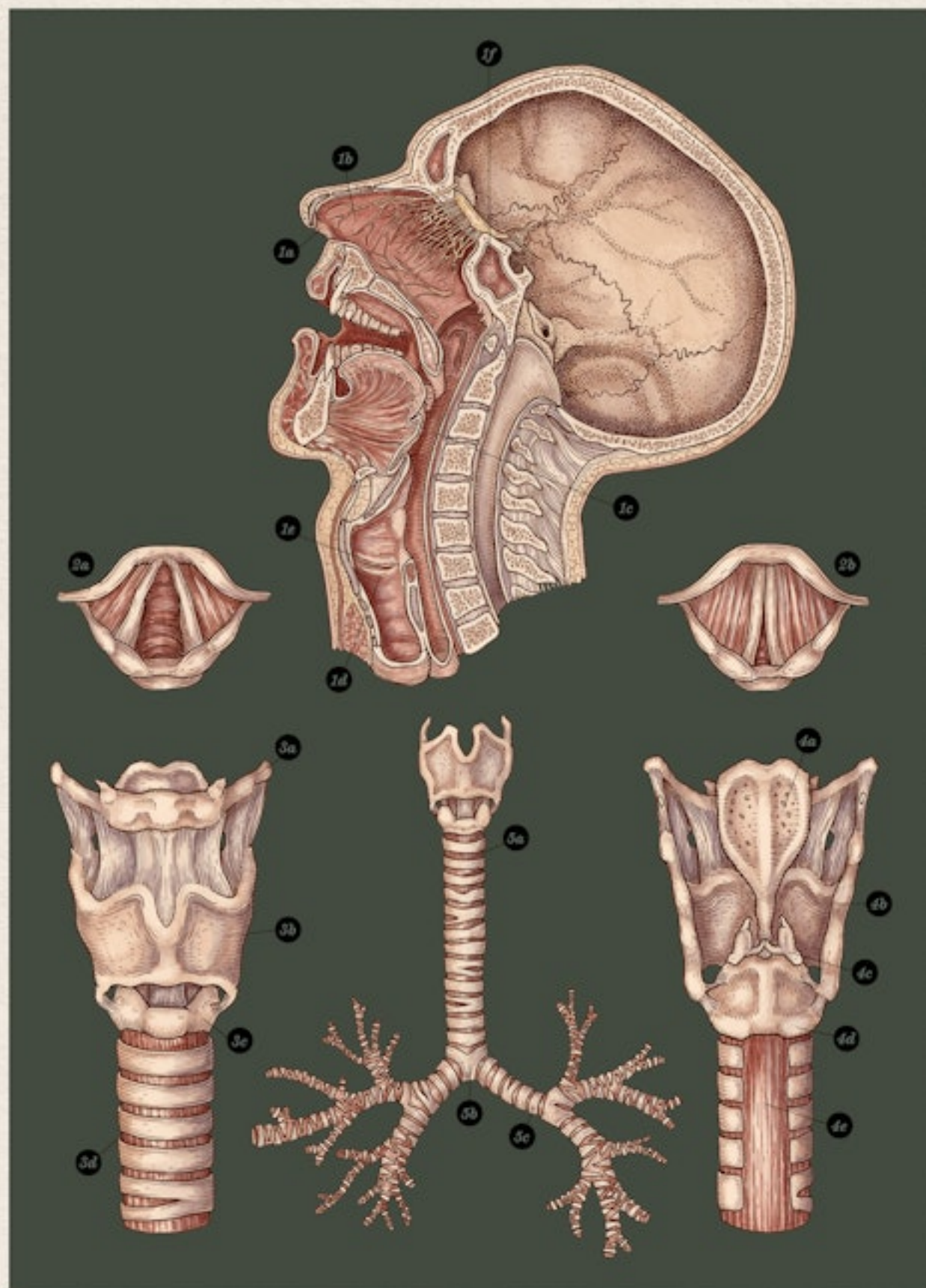
- a) Epiglottis: A flap in the throat

which closes over the larynx during swallowing to stop any food or drink entering the lungs.

- b) Thyroid cartilage
- c) Arytenoid cartilages: These protrusions look like two shark fins, and help in generating movements of the vocal cords.
- d) Cricoid cartilage
- e) Trachealis A muscle that constricts the larynx during sneezing or coughing.

### 5: Lower respiratory tract

- a) Trachea
- b) Carina: The branching point of the trachea into the two primary bronchi
- c) Bronchi: Here, the airways enter the lungs, where they begin to branch into smaller and smaller air passages.





# The Lungs

We breathe over 10,000 litres of air each day to keep our cells alive and healthy. Getting all of this air in and out of the body is the responsibility of the lungs. These paired organs inhale and exhale air at a rate of around 15 breaths a minute, and transfer oxygen from inhaled air into the bloodstream, while passing carbon dioxide from the bloodstream into the air to be exhaled.

Once air enters the lungs, it begins a journey through a dividing network of more tubes, that become smaller and smaller as they travel deeper into the organ. Eventually, the air reaches tiny closed sacs called alveoli, which resemble small bunches of grapes. Each individual alveolus (singular of alveoli) is covered in a tiny blood vessel called a capillary (see page 32). The walls of the alveoli and the capillaries are only one cell layer thick (less than a thousandth of a millimetre), so gases can easily be exchanged to and from the blood. There are several hundred million alveoli in an adult's lungs, meaning they have a huge surface area in order to quickly transfer as much gas as possible. In fact, the total surface area of the lungs is estimated to be bigger than that of a tennis court!

The right and left lungs sit within the chest, under the ribcage. The right lung has three different parts, or lobes, and is a little bigger than the left, which only has two lobes. The left lung is smaller to make room for the heart that fits snugly between the two lungs. A large, dome-shaped muscle called the diaphragm is found directly underneath the lungs, separating them from the organs in the abdomen. The diaphragm helps to create space in the chest when we breathe in, or inhale, by pulling downwards and flattening out. This lets the lungs fill with air, inflating like balloons and raising the ribcage outwards. When we breathe out, or exhale, the diaphragm relaxes and pushes on the lungs, squeezing the air back out again. This cycle happens between 12 and 20 times each minute when resting and much more often during exercise as breathing rate increases.

## Key to plate

### 1: Lungs

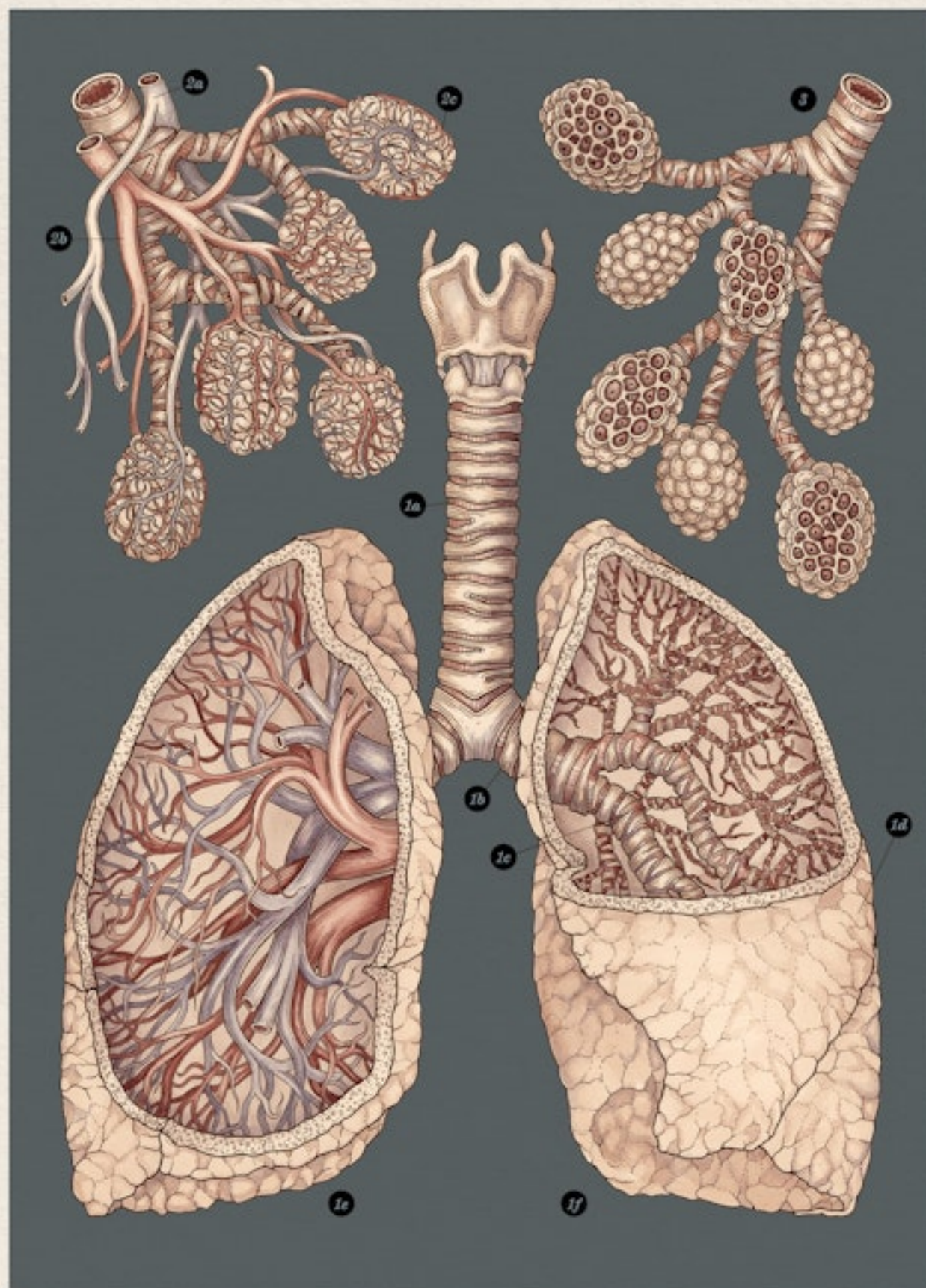
- a) Trachea
- b) Bronchi
- c) Bronchioles
- d) Pleural membranes: Two thin, fluid-filled membranes encase the lungs. They enable them to move smoothly as the lungs inflate and deflate.
- e) Right lung
- f) Left lung

### 2: Alveoli

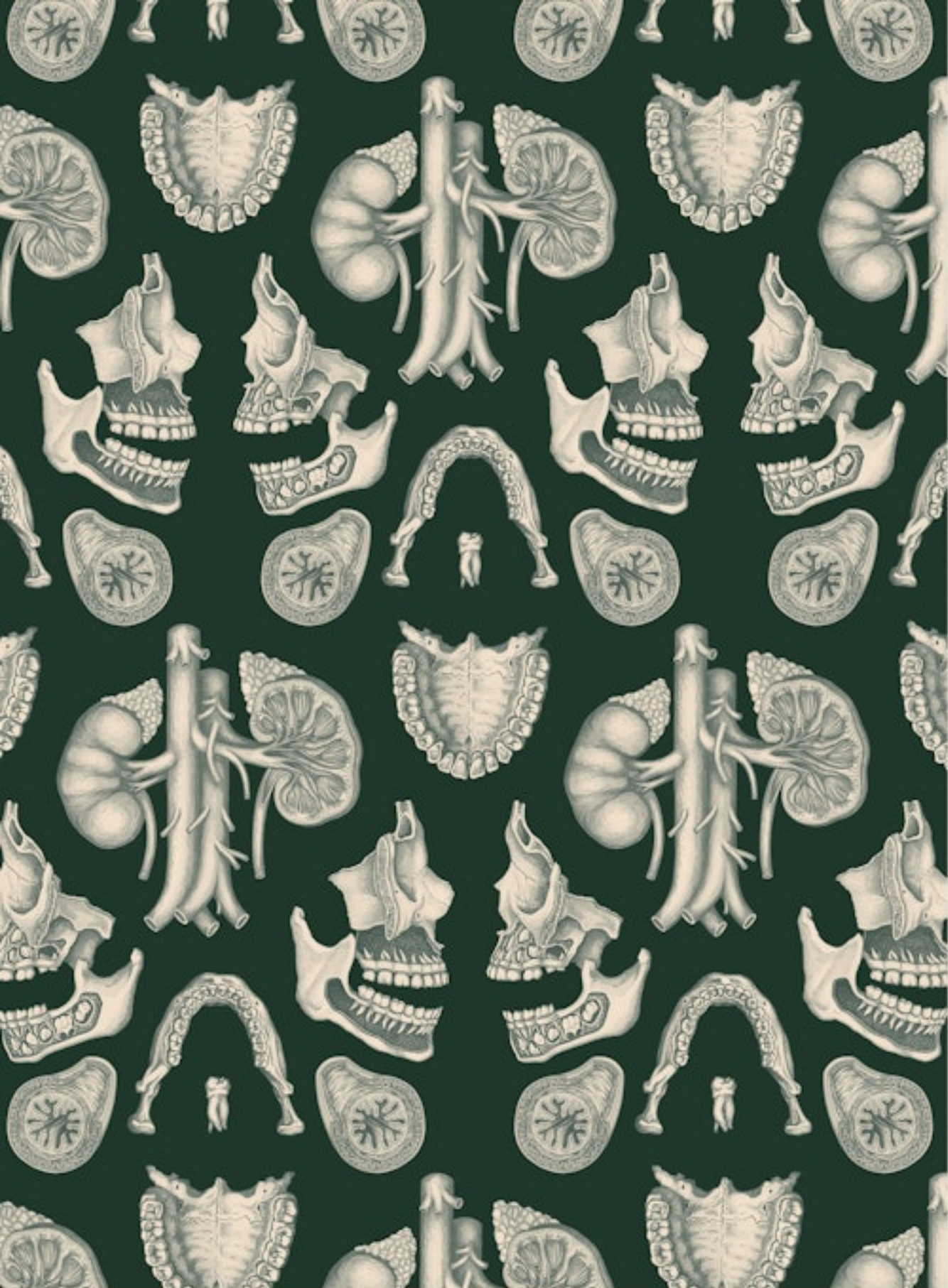
- a) Venule
  - b) Arteriole
  - c) Capillary bed
- The millions of alveoli in each lung group together to form small bunches. Tiny capillaries wrap around them so that gas can easily transfer between the blood and the air in the alveoli.

### 3: Cross-section of alveoli

Inside each grape-like cluster are dozens of individual alveoli. Each one has a wall just one cell-layer thick, so oxygen can enter the bloodstream as easily as possible.



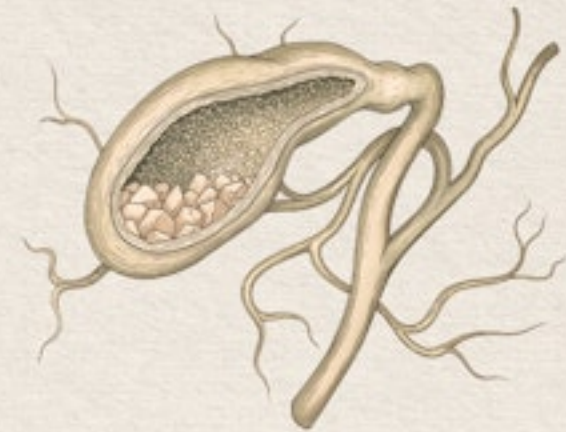



ANATOMICUM

Gallery 3

# The Digestive & Urinary Systems



*The Digestive System*  
*The Mouth & Throat*  
*The Teeth*  
*The Stomach*  
*The Intestines*  
*The Liver*  
*The Pancreas & Gallbladder*  
*The Urinary System*  
*The Kidneys*



# The Digestive System

The digestive system is a clever food-processing plant, working constantly to take in food, break it down into the nutrients we need, and get rid of the waste that's left. The main part of the system is the digestive tract – 7 metres of long, muscular tubes, most of which are squashed into the body's abdomen. It is made of seven interconnected organs, which effectively form a direct path all the way from the mouth to the anus.

Food enters the body via the mouth, where it is chewed and swallowed, passing through the pharynx (throat) and into the oesophagus (food pipe) on its way to the stomach. There, food is broken down into a thick, soup-like liquid before being passed into the small then the large intestine. The intestines are where essential nutrients are absorbed from digested food into the bloodstream. Once in the large intestine, the waste material forms faeces (or poo), before leaving the body through the rectum and anus.

The process of breaking down food to generate energy is known as digestion. Its main task is to turn complex food molecules into smaller ones the body can use. First of all, food is digested mechanically: broken down into physically smaller chunks as the body crushes and mashes it, initially by chewing food in the mouth, then by churning and mixing it using the muscles of the stomach. Food is also digested chemically: special molecules called enzymes (found in saliva in the mouth, and released as a liquid into the stomach and intestines) break nutrients such as fats, proteins and carbohydrates into even smaller parts such as amino acids, for building new molecules, and glucose for energy.

Although the digestive tract is the main path that food takes through the body, it does not work alone: the liver, gallbladder and pancreas all aid digestion by releasing special chemicals into it. Controlling all the complex processes of eating, digestion and excretion are a combination of nerve signals and hormones. Emotions can affect the digestive system, too, as you will know if you have ever felt the sensation of 'butterflies in your stomach' when you are nervous, or if you have felt sick with excitement.

## Key to plate

### 1: The mouth (oral cavity)

The opening to the digestive system, where food and drink enter the body.

### 2: The pharynx (throat)

This connects the mouth to the oesophagus.

### 3: The oesophagus

A long, muscular tube that connects the pharynx to the stomach.

### 4: The stomach

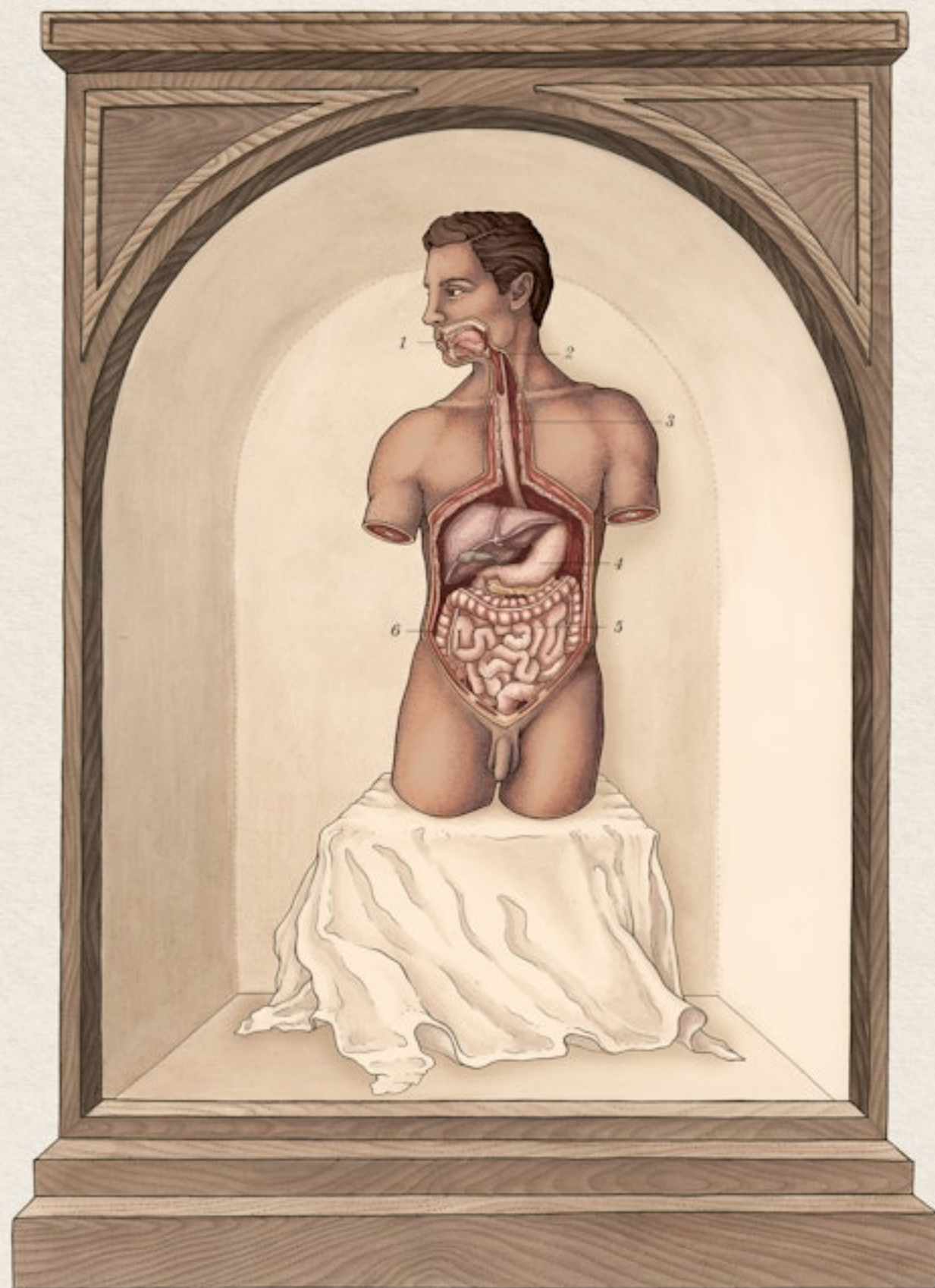
A large, muscular bag that stores and digests food.

### 5: The small intestine

A long passageway that joins the stomach to the large intestine: digested food is passed through the small intestine, where the nutrients it contains are absorbed into the body's bloodstream.

### 6: The large intestine

The waste products of digested food pass through the large intestine, where any remaining water is absorbed back into the bloodstream. The remaining dry waste then passes to the rectum and anus where it will exit the body.





# The Mouth & Throat

The oral cavity, known as the mouth, is the gateway to the body: this is where all food and drink starts its journey through the digestive system. Even before you take your first bite of food, your body begins to prepare itself for digestion. The smell of food cooking (or sometimes just the thought of a tasty meal) is enough to kick-start the salivary glands into action. They pump out a watery liquid called saliva – on average over 2 litres each day – literally making your mouth water. As well as making the food you eat wetter and easier to swallow, saliva contains chemicals called enzymes, which start to break down complex molecules within food. Teeth also grind food down mechanically, and, together with the tongue, help shape food into a slimy ball called a bolus, which is easy to swallow.

At the moment of swallowing, an important safety mechanism kicks in at the top of the pharynx (throat). A small trapdoor called the epiglottis swings into place, covering the entrance to the trachea (windpipe) as food and drink slips into the oesophagus (food pipe). This ensures no food or drink accidentally enters the respiratory system. Sometimes the epiglottis fails and things 'go down the wrong way' – but a cough is usually enough to clear the airway again, and no harm is done.

Once a food bolus has passed the epiglottis, it travels down the oesophagus, a long, muscular tube. Rather than acting as an open chute that food simply falls down, the muscles of the oesophagus squeeze the bolus down towards the stomach. Incredibly this means food would still reach the stomach even if you were standing on your head!

## Key to plate

### 1: The mouth (oral cavity)

**a) Teeth:** The 32 teeth are used to rip, tear and grind food into smaller pieces that can be swallowed.

**b) Tongue:** This muscular organ is made up of several muscles, the largest of which is the genioglossus. During swallowing, the tongue shapes the food and pushes it towards the back of the mouth.

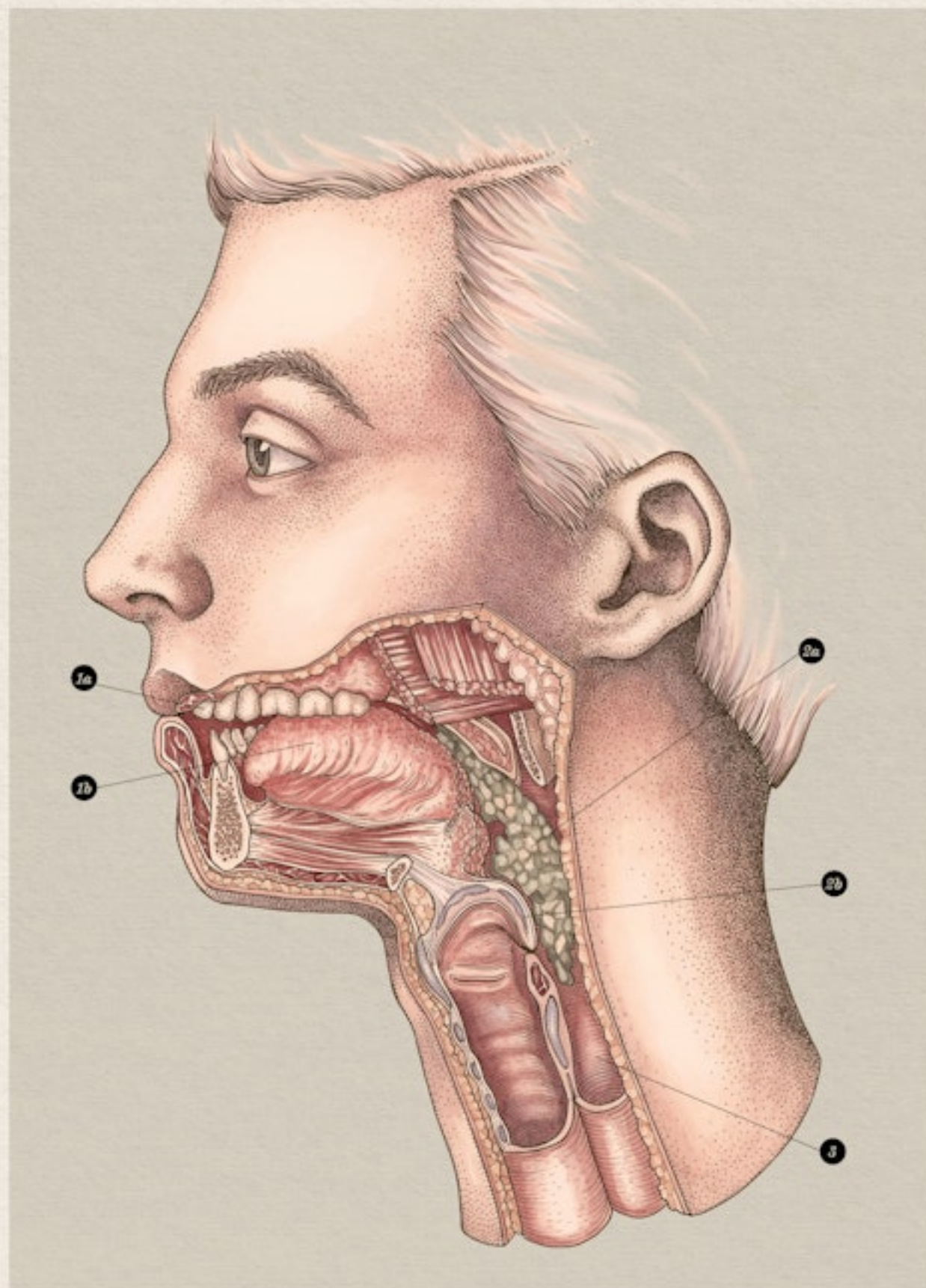
### 2: The pharynx (throat)

**a) Food bolus**

**b) Epiglottis:** Although it is usually classed as part of the respiratory system, the epiglottis has an important role in the digestive system. During swallowing, it folds over the larynx, stopping food from entering the airways.

### 3: The oesophagus (food pipe)

This muscular tube, approximately 25cm long, runs from the pharynx to the stomach, transporting the food bolus on into the rest of the digestive system.





# The Teeth

The adult mouth (oral cavity) contains 32 teeth, arranged in two neat rows across the upper and lower jaws. Their job is to make food soft, smooth and suitable for swallowing.

Babies are usually born without any teeth at all, and the first tooth will push through the gums when a child is around six months old. Slowly, the teeth emerge into the mouth, and children have a full set of 20 'baby teeth' or 'milk teeth' by around three years of age. As children grow up, the baby teeth start to be pushed out by permanent adult teeth that lie in the jaws behind them. By the time most people enter their thirties, they have 32 teeth in total, including four wisdom teeth at the very back of the mouth, which only come through in the teenage years – and often with some disruption! This final set of adult teeth needs to last for an entire lifetime, since teeth cannot repair themselves. Holes can appear in the teeth due to decay and these need to be repaired by a dentist. If the decay is too severe, or a tooth is damaged through trauma, the whole tooth is sometimes removed.

The shape of a tooth and its position within the mouth are good indicators of their function. At the front of the mouth are the incisors: sharp, thin teeth that easily slice into food. Next to the incisors are the canines, more pointed in shape and also used to bite, tear or hold food. Premolars and molars, which sit at the back of the mouth, have a flat, squarish shape with ridges on their top surface. The molars, especially, are ideally shaped to crush and grind food during chewing.

Each tooth is made up of several layers. The outer layer of enamel acts like a protective armour encasing the crown (top) of the tooth, and gives teeth their whitish colour due to its high levels of minerals such as calcium. Underneath the enamel lies the dentine, a hard substance that protects the dental pulp in the centre of the tooth – a soft cushioning around the tooth's sensitive blood vessels and nerves. The bottom part of the tooth, the root, sits buried deep into the gums overlying the jawbone. Individual teeth are anchored into the jaw by fibrous joints covered in a layer of cementum. As the name suggests, this substance keeps the tooth firmly cemented in place.

## Key to plate

### 1: Adult's skull

The roots of the teeth reach deep into the jaw bones.

### 2: Child's skull

Here we can see the permanent teeth developing behind the milk teeth. They push into the mouth during childhood, loosening and eventually pushing out the milk teeth.

### 3: Types of adult teeth

a) Molars (12): The molars, including wisdom teeth, which appear during

adulthood, have flat, wide surfaces

shaped to grind and mash food.

b) Pre-molars (8): Smaller in size than the molars, these also grind food.

c) Canines (4): There is one canine on the upper and lower jaws at each side. They are used to bite or tear

food using their sharp, pointed surface.

d) Incisors (8): There are four incisors on the upper and lower jaw. Their flat, thin shape acts like a knife, biting food.

4: Upper jaw (maxilla), from below (inferior view)

5: Lower jaw (mandible), from above (superior view)

### 6: Structure of a tooth

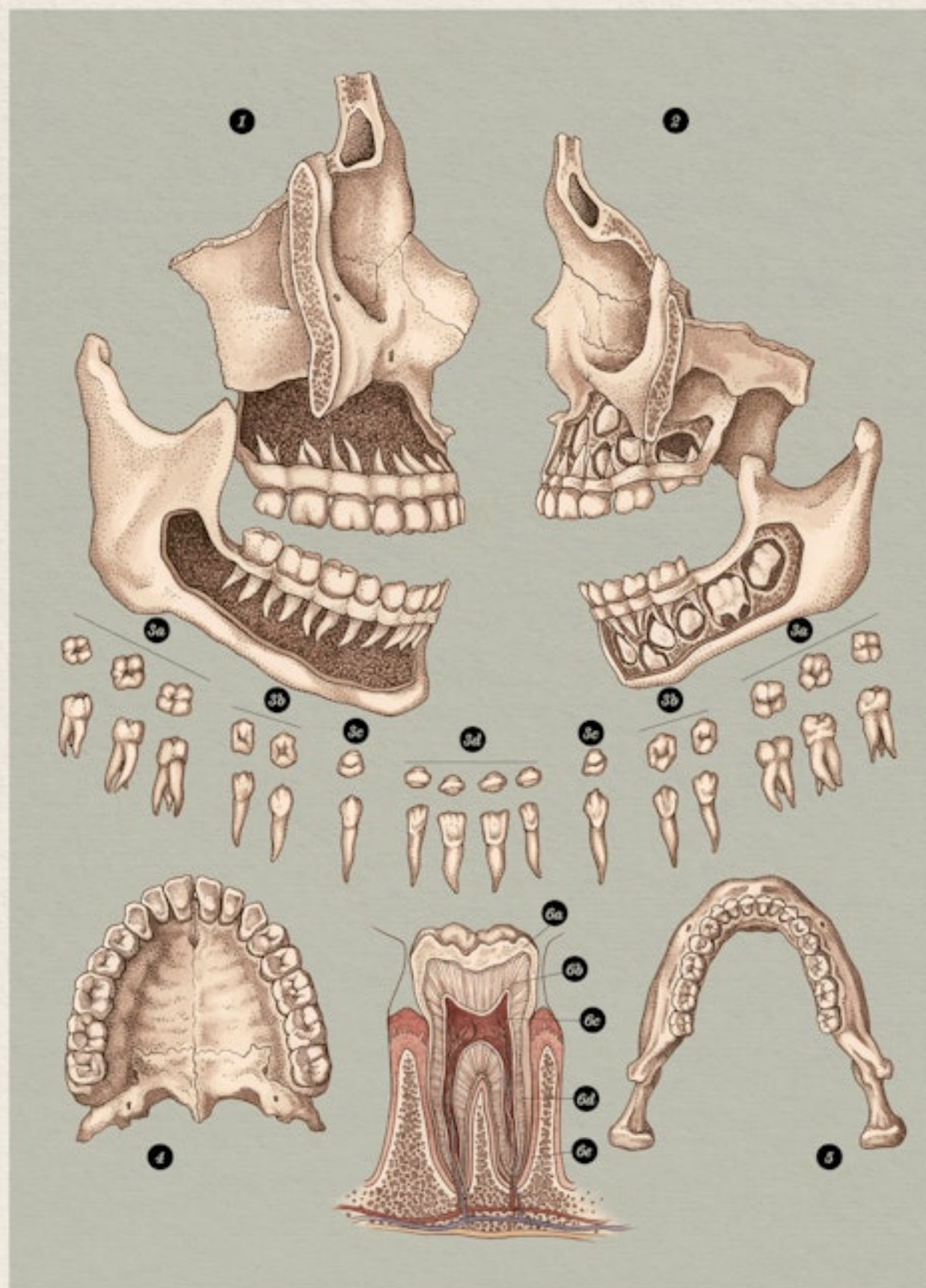
a) Enamel: A tooth's hard outer layer

b) Dentine: This lies beneath the enamel.

c) Pulp: Soft dental pulp lies within the inside of the tooth and contains blood vessels, cells and nerves.

d) Root: The root is the part of the tooth secured into the gums.

e) Cementum: This hard substance surrounds the root of the tooth and secures it in place in the jaw.





# The Stomach

After food has been swallowed, it is transported to the stomach: a curved, muscular bag in the upper left region of the abdomen. The stomach stores the food we eat while vigorously churning to mix it with stomach acid. Then the resulting mixture – a thick, creamy soup called chyme – is passed on to the next part of the digestive tract.

About 1.5 litres of stomach acid, or gastric juice, is produced by cells in the stomach lining every day. It chemically digests food by breaking down long molecules into smaller ones (see page 40). It also helps to kill any dangerous bacteria present in the food. A layer of mucus on the stomach lining stops the wall of the stomach from being damaged by the acidic juice. Occasionally an infection can stop mucus production, meaning the acid starts to eat away at the stomach, producing a hole or painful ulcer.

The walls of the stomach are made from smooth muscle, arranged into three separate layers. The fibres in these overlapping muscle layers run in different directions, from left to right, top to bottom and diagonally around the stomach walls. This means that when they contract, the stomach moves in a 'churning' or mixing motion, helping to blend the soup-like chyme. Have you ever heard your stomach 'rumble' when you haven't eaten for a while? This is just the normal sound of the movement of the stomach as it churns. When the stomach is empty, it fills with gas and without any food to muffle the noise, the growling sounds much louder. At its fullest, an adult stomach can hold approximately 1 to 2 litres of food and drink. To cope with the need to expand, the inside walls of the stomach are folded into numerous ridges that fan out, stretching the walls as the stomach fills up. Special sensors in the stomach wall can tell if the stomach is stretched, giving you a feeling of 'fullness'.

Food can stay in the stomach for as little as 20 minutes or many hours depending on what has been eaten. Simple, easy-to-digest foods like cooked fruit and vegetables will be digested fairly quickly, but rich, greasy foods may take several hours. Once ready to leave the stomach, a special valve at its base will let small amounts of chyme through to the small intestine, carefully controlling the speed at which the food makes its journey through the body.

## Key to plate

### 1: Oesophagus (food pipe)

The muscular tube leading from the pharynx (throat) to the stomach.

### 2: Cardiac sphincter

This ring of smooth muscle acts like a valve to let food into the stomach, while preventing food and stomach acid from travelling back up into the oesophagus.

### 3: Layers of the stomach wall

- a) Oblique muscles
- b) Circular muscles
- c) Longitudinal muscles

### 4: Stomach

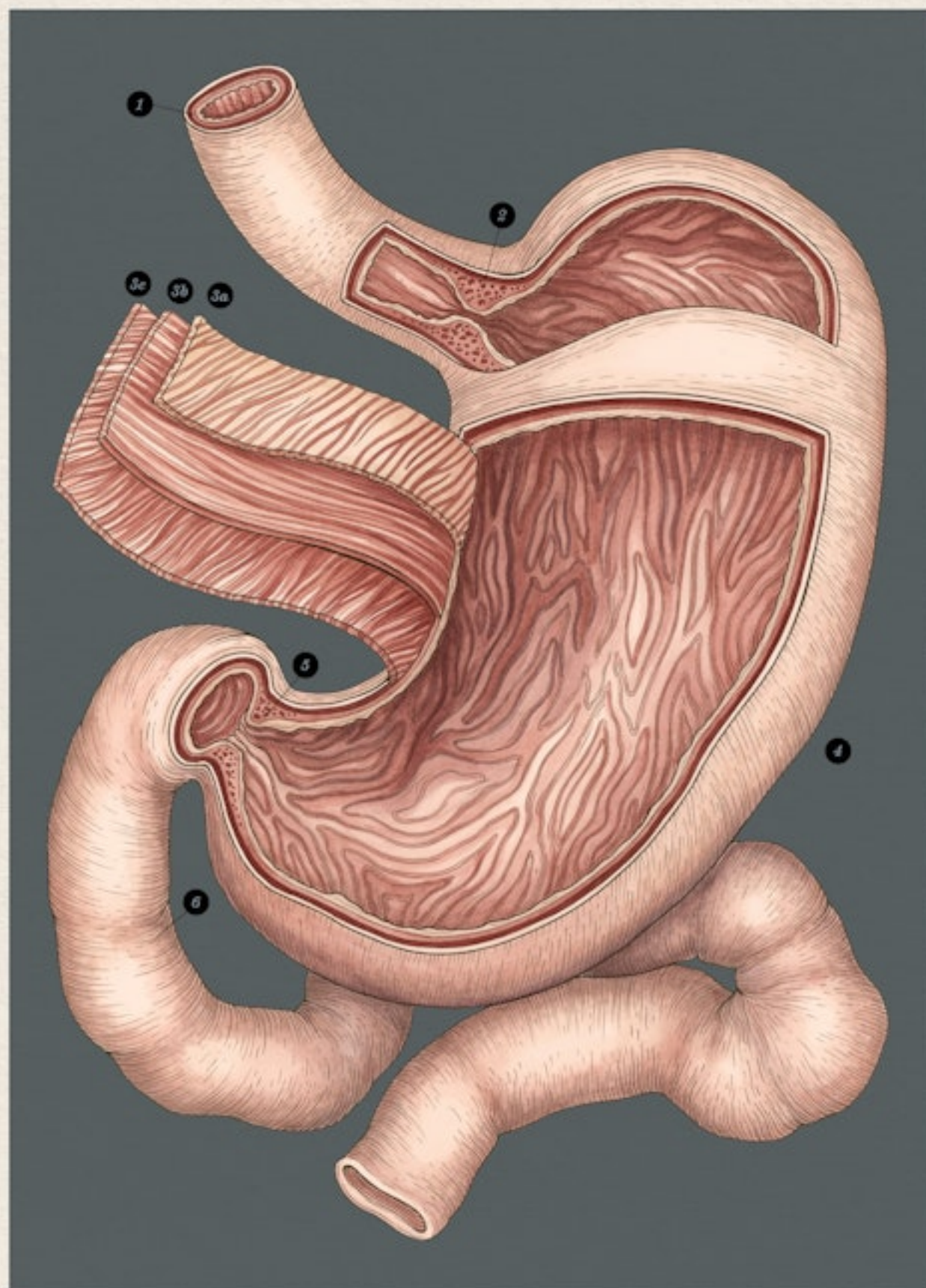
The inner surface of this muscular bag has thick folds, called rugae. These stretch as the stomach fills and allow the stomach to expand in size.

### 5: Pyloric sphincter

A ring of smooth muscle which ensures the controlled release of chyme from the stomach to the small intestine, and prevents the backflow of the chyme into the stomach.

### 6: Duodenum

This is the first portion of the small intestine.





# The Intestines

The long, sausage-like tubes of the small and large intestines are where the main process of digestion and absorption takes place (see page 40). Despite its name, the small intestine is actually the longest part of the digestive system. In fact, the terms 'small' and 'large' refer to the width of the intestines rather than their length. Beginning at the exit of the stomach, the small intestine is made of three parts: the duodenum, the jejunum and the ileum. The short, curved duodenum is where acidic chyme from the stomach meets alkaline fluids secreted by the liver, gallbladder and pancreas, reducing the acidity of the chyme and making sure that the intestine's digestive enzymes can work properly. After this, chyme is propelled along the loops and coils of the jejunum and ileum by regular waves of muscle contractions called peristalsis. Along its way, the chyme continues to be digested and absorbed.

Aside from being very long, the walls of the small intestine are tightly folded and covered with millions of tiny finger-like projections called villi. Together, these hugely increase the surface area of the intestines – stretched out they would cover an area of about 250 square metres. This lets absorption of nutrients and water happen quickly and easily, passing straight into the blood vessels within the villi.

Once chyme reaches the large intestine, or colon, the body has already absorbed most of the nutrients it contains, leaving behind a mix of water and waste material to be disposed of. As the chyme is pushed through the 1.5 metres of large intestine, its water content is absorbed back into the body. This process can take a long time (up to 40 hours), but it is essential to dry out the chyme and make solid waste called faeces, or poo. Faeces is stored in the rectum until you need to visit the toilet, where it exits the body through the anus.

## Key to plate

### 1: Small intestine, surface view

The long tube where most nutrients are absorbed during digestion. It is split into the duodenum, ileum and jejunum, though these parts are hard to distinguish by appearance alone.

### 2: Large intestine, surface view

This is where water is absorbed from food waste before it leaves the body. The puckerings of the large intestine are called haustra.

**a)** Rectum: The part of the large intestine where faeces is stored

**b)** Anus: The exit point of the large intestine, where faeces leaves the body

**c)** Tonsa Coli: A line of muscle visible on the outside of the large intestine

### 3: Cross-section of small intestine

**a)** Inner mucosa: Its folded surface lined with villi give this layer a high surface area for increased absorption.

**b)** Submucosa: This layer carries blood vessels, nerves and lymphatic vessels.

**c)** Muscular layers: Two connecting layers of muscle contract to propel food along the digestive tract.

**d)** Outer covering (serosa):

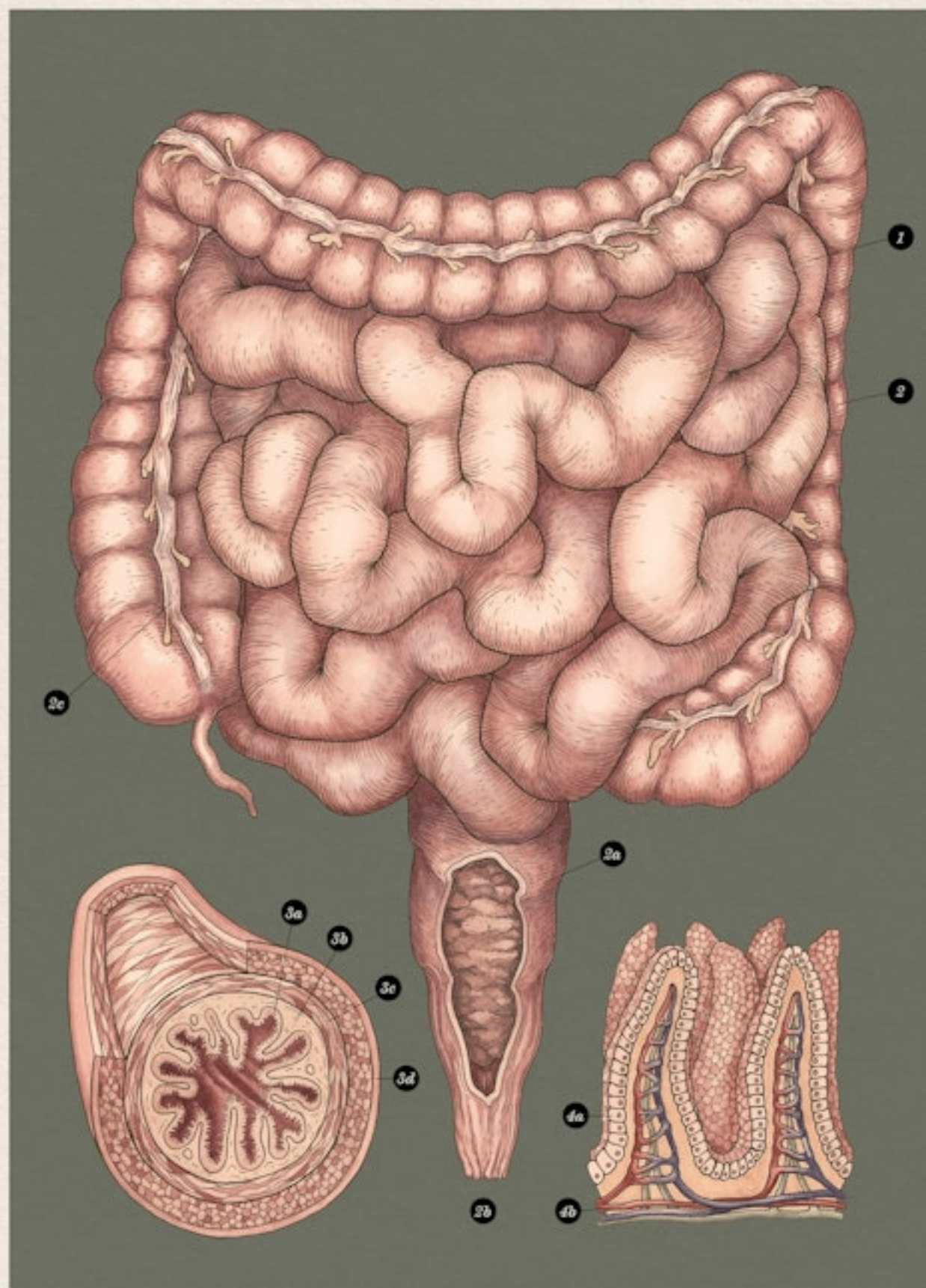
A connective tissue coating

### 4: Villi of the small intestine

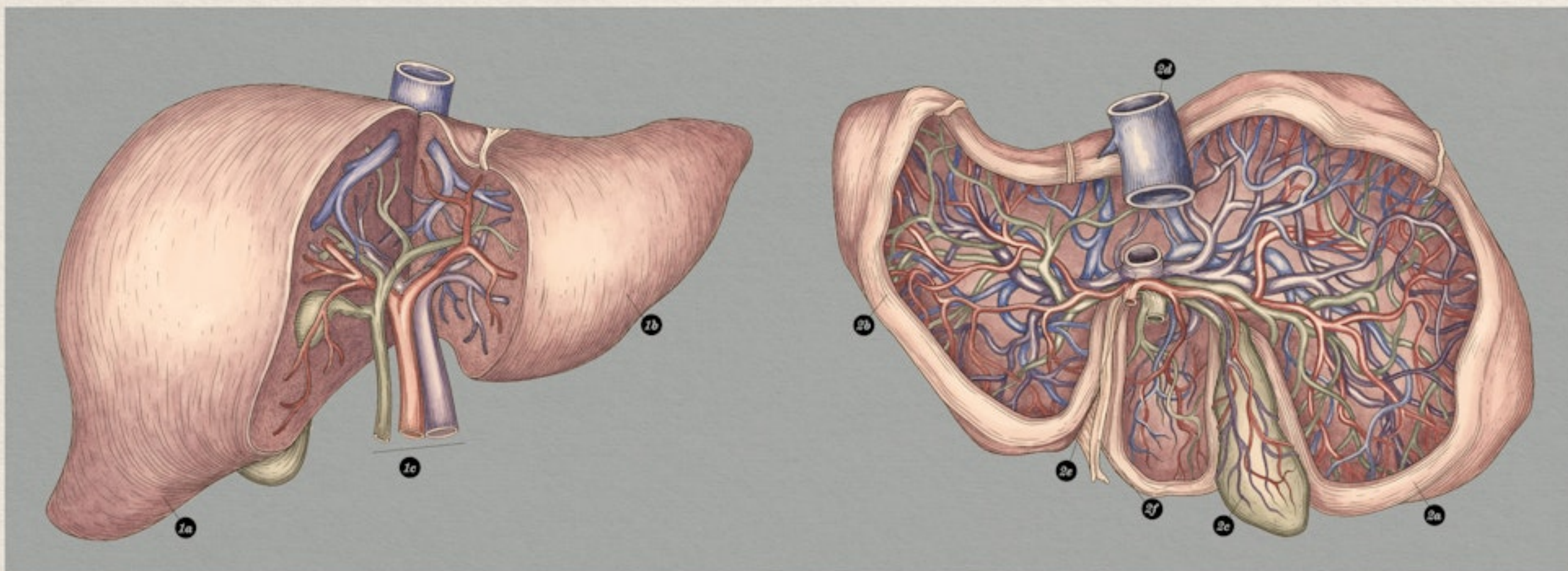
Fingerlike projections called villi line the small intestine, increasing its surface area so nutrients can quickly be absorbed into the bloodstream.

**a)** Epithelial layer: This top layer is just one cell thick.

**b)** Blood and lymphatic vessels (see page 76)







## The Liver

The liver carefully orchestrates hundreds of processes to keep the blood clean and the body healthy. As the largest organ inside the body, it sits in the upper right region of the abdomen, just under the ribcage and diaphragm. It is roughly triangular in shape with four different parts, or lobes, and is a deep red colour because of its extensive blood supply. Indeed, the liver receives over 10 per cent of all the blood in the body at any one time, and pumps an astonishing 1.5 litres of blood through it every minute.

The liver serves three major roles: cleaning the blood, producing bile and storing energy. First, the liver cleans the blood, removing any substances that might be harmful. These can be leftover products of food after digestion or toxins such as medicines or alcohol. Often, the liver can change toxins into molecules that are less harmful to the body. Otherwise it sends the toxins via the digestive system to exit the body in faeces, or via the kidneys to leave the body in urine. Second, the liver makes bile: a thick, yellow-green liquid that is needed to help the body digest fat. Bile is either released into the small intestine straight away, or is sent to the gallbladder to be stored until needed. Third, the liver stores and produces energy, like a battery that charges and bursts into action when energy levels are low. The liver is 'charged' by blood coming from the small and large intestines, packed full of the nutrients absorbed during digestion.

From the intestines, the blood is directed via the liver through a special set of blood vessels known as the hepatic portal system. Any toxins in this blood will also reach the liver this way, to be filtered out and removed from the body.

Interestingly, the liver has an amazing feature shared by no other organ in the human body: it can regenerate. Damage to the liver, caused by disease or too much alcohol, can stop it working properly and make a person very ill. However, if the damaged parts of the liver are removed (leaving at least a third behind), the rest of the liver can actually grow back and become full size again.

### Key to plate

#### 1: Liver, seen from the front (anterior view)

- a) Right lobe
- b) Left lobe
- c) Hepatic portal system: Blood travels to the liver from the small and large intestines (where it becomes rich in nutrients). Oxygen-rich blood also arrives at the liver from the main blood supply of the abdomen. Meanwhile bile made in the liver is

transported through here to the gallbladder for storage, or straight to the small intestine.

#### 2: Liver, seen from behind (posterior view)

- The liver has a very extensive blood supply.
- a) Left lobe
- b) Right lobe
- c) Gallbladder

d) Inferior vena cava: Blood leaving the liver exits here on its way back to the heart.

- e) Hepatic portal vein: Blood coming from the intestines enters the liver here.
- f) Falciform ligament: This connective tissue structure divides the liver into left and right lobes. It also helps to attach the liver to the inside of the abdomen.



# The Pancreas & Gallbladder

The pancreas has an important role to play both in the digestive system and the endocrine (hormonal) system (see page 80). Leaf-shaped and uniquely textured, it lies near the stomach, with its head nesting snugly into the curve of the duodenum (the first part of the small intestine). This position enables it to release pancreatic juice directly into the intestines, neutralising acidic chyme before it travels any further through the digestive system.

When a gland (an organ that secretes chemicals) releases a substance straight into an organ or tissue like this, it is known as an exocrine function. The pancreas is a special gland as it also has an endocrine function, meaning it releases chemicals directly into the blood as well. Two of the chemicals produced by the pancreas are insulin and glucagon, which are important hormones for controlling sugar levels. If levels are low, you might feel dizzy or light-headed; then the pancreas produces glucagon to tell the liver to release sugar. If your sugar levels are too high, the pancreas produces insulin, which reduces the amount of sugar in the blood. Sometimes, the pancreas stops producing these hormones in a condition called diabetes, and insulin injections are needed to help control sugar levels.

The point where pancreatic juice enters into the small intestine is shared by the entrance of another liquid crucial for digestion: bile. Bile is made in the liver, but is stored in a small muscular bag called the gallbladder. Although it is mostly made from water, bile also contains lots of salts and fats, which, in some people, can stick together and form small stone-like deposits called gallstones. These can be harmless, but if a stone escapes the gallbladder and enters the passageway between the gallbladder and the intestines (the bile duct), it can cause intense pain. Some people get their gallbladders removed if they experience pain regularly, and can live normal lives without them.

## Key to plate

### 1: Gallbladder

A pouch-shaped organ that stores the bile made by the liver. Bile helps to digest fats, and is released into the duodenum of the small intestine after eating.

### 2: Duodenum

The first section of the small intestine is curved in shape. The openings of

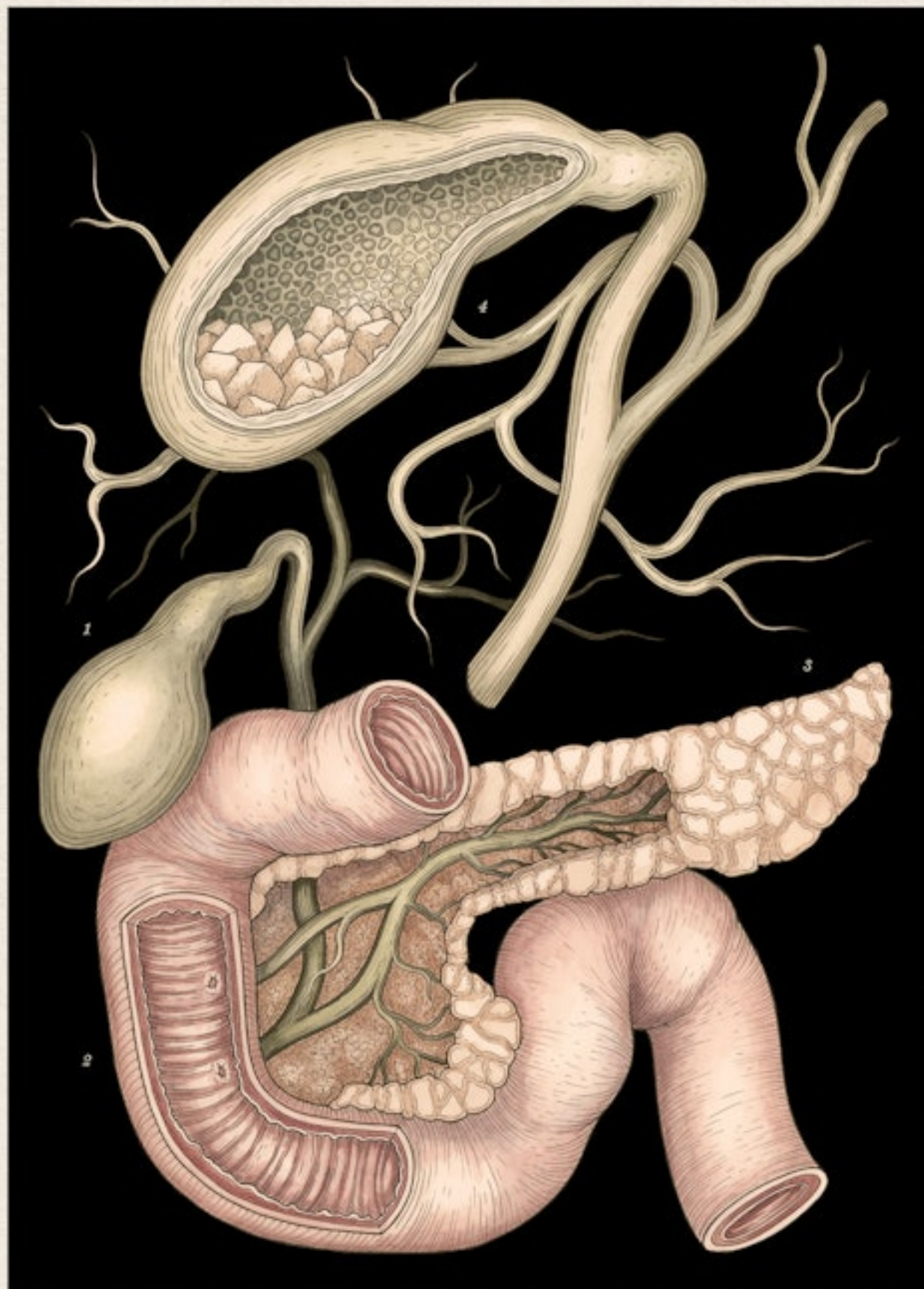
the common bile duct (from the gallbladder and liver) and the pancreas are in the duodenum. These organs produce important substances for the digestion of food.

### 3: Pancreas

Pancreatic juice is produced in the pancreas and emptied into the duodenum.

### 4: Gallbladder with gallstones

Quite often, the salts within bile can form little deposits, like stones, that sit within the gallbladder. Normally, these gallstones are harmless, but if one escapes the gallbladder, it can block the tube running between the gallbladder and the duodenum and cause severe pain and inflammation.





# The Urinary System

The body's own plumbing system, the urinary system, is a collection of organs responsible for taking waste products from the blood and turning them into urine (pee) to leave the body when you urinate. The entire system sits within the abdomen and the pelvis. The two kidneys are found high up on the back wall of the abdomen, close to the liver on the right and the stomach and small intestine on the left. The kidneys do most of the hard work in the urinary system, as this is where urine is made. The rest of the system is a collection of passageways and storage areas for urine until it leaves the body.

Once urine has been made in the kidneys (see page 56), it drips down the thin tubes of the ureters, each about 30 centimetres long. Smooth muscle in the ureters contract to push urine down to the muscular bag of the bladder, where the urine is stored. The bladder stretches as it fills with urine and can hold around 500 to 600 millimetres of liquid at once, although the need to visit the toilet is usually felt well before then. Special nerve sensors in the wall of the bladder get stretched as the bladder fills, letting the brain know that you need to urinate. When ready, the urine leaves the body through a thin pipe called the urethra.

Urine is mostly water but also contains waste products such as urea, which is made when proteins are broken down, and other toxic chemicals the body cannot process. It also contains the chemical urobilin, which is produced when the body recycles old blood cells, and is what gives urine its yellowish colour. The colour of urine lets us know how well hydrated a person is: a light colour shows high water content, whereas a dark colour means the pigment is more concentrated, and that the person has not had much to drink. This is an easy way to see if you are becoming dehydrated and need to drink more water – most people should drink around 2 litres a day.

## Key to plate

### 1: Blood supply to the kidney (renal artery)

Oxygenated blood from the heart enters the kidneys here for filtration.

### 2: Blood supply from the kidney (renal vein)

Deoxygenated blood leaves the kidneys here.

### 3: Left kidney

Positioned high in the body, the right and left kidneys both produce urine.

### 4: Right kidney

The right kidney is usually slightly lower in the body than the left kidney. This is because the large liver takes up a lot of room on the right side.

### 5: Ureters (right and left)

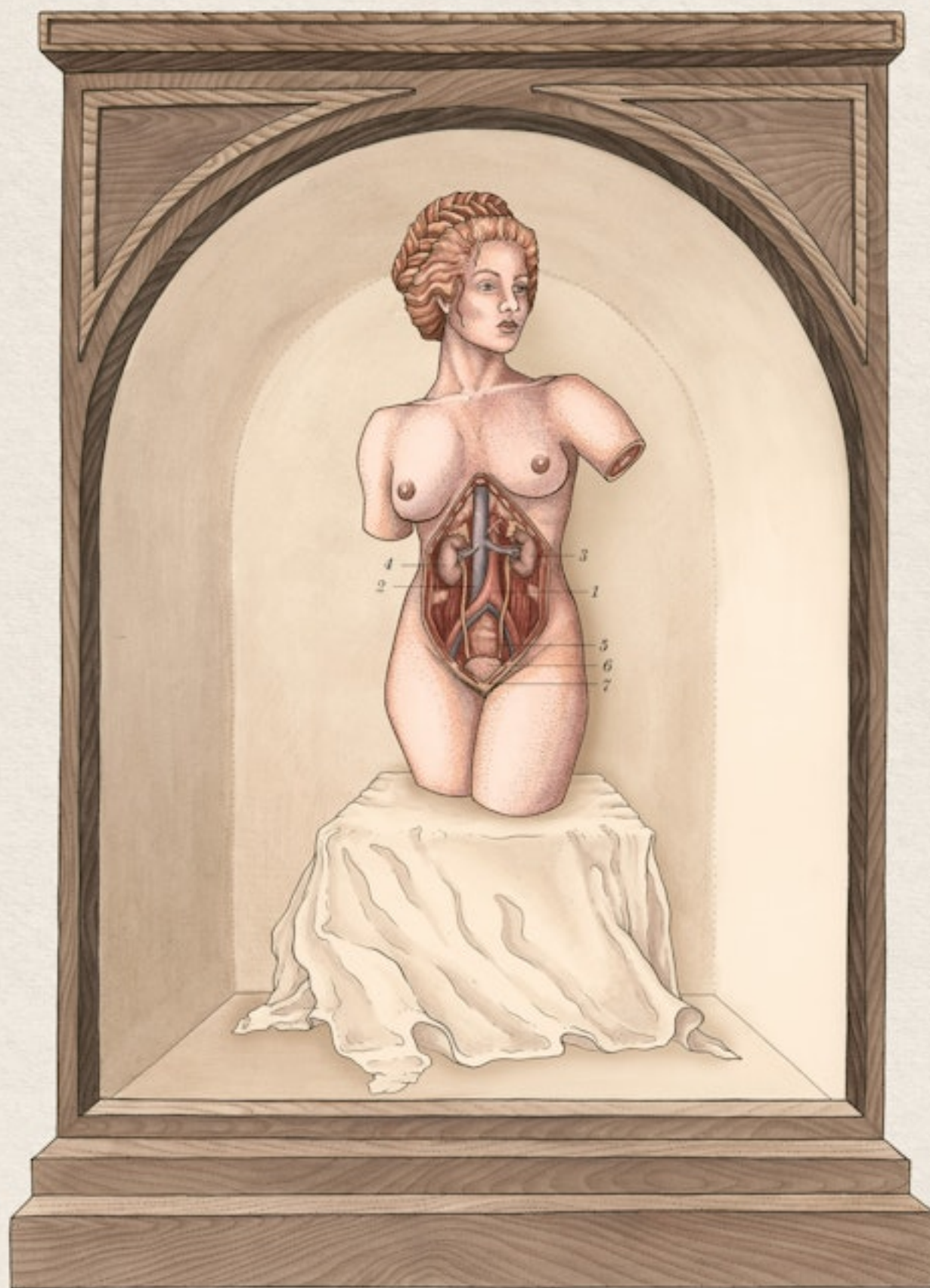
The ureters are two long muscular tubes. They connect each kidney to the bladder providing a pathway for urine to travel along.

### 6: Bladder

The bladder sits in the pelvis and stores urine until it is ready to leave the body.

### 7: Sphincter

This ring of muscle controls the emptying of the bladder.





# The Kidneys

The two bean-shaped kidneys are positioned towards the back of the abdomen just beneath the ribcage. Each one is about 10 to 15 centimetres tall and works tirelessly to clean the body's blood. They do this by pumping blood through over one million tiny filters called nephrons. These remove waste products made during the body's chemical reactions, pass the toxins into our urine, and re-absorb any substances the body needs to keep. To do this, the kidneys have an extensive blood supply, receiving 20 per cent of the body's blood volume at any time. It is estimated that all the blood inside the body is passed through the kidneys over 40 times a day.

The kidneys also have vital roles in the overall balance of water and salts in the body. If the body is low on either, the kidneys can absorb more from the blood it is filtering, reducing the amount of urine made. On the other hand, if there is too much fluid in the blood, the kidneys can stop absorbing and the body will create more urine.

Healthy kidneys are vital to living a normal life. Thankfully, because we have two kidneys, if one gets damaged or stops working, the other can take over the role of both. This means it is possible to live with just one kidney. If both kidneys stop working though, the blood cannot be cleaned and dangerous disease-causing toxins start to build up. People without any working kidneys need to have dialysis, where blood is pumped out of the body and through an external machine which filters their blood. This process takes several hours, and has to be carried out around three times a week. A potential way to help treat kidney disease is by organ transplantation, where a working kidney is transferred into a patient from a living, or recently deceased, donor. Kidney transplants have been performed for over 50 years with very good success rates. Interestingly, if a patient receives a new, working kidney, it is placed in the area of the pelvis rather than the normal kidney position in the abdomen and the non-working kidneys are not usually removed.

## Key to plate

### 1: Right kidney

The right kidney sits lower than the left because of the large liver on the right-hand side of the abdomen.

### 2: Left kidney

**a)** Renal artery (left): A large blood vessel which supplies oxygen-rich blood to the kidneys.

**b)** Renal vein (left): This blood vessel drains oxygen-poor blood from the kidneys and takes it back to the heart.

**c)** Renal cortex

**d)** Medulla: The cortex and medulla are where blood is filtered through millions of tiny units called nephrons.

### 3: Ureter

A long muscular tube that connects the kidney to the bladder.

### 4: Adrenal gland

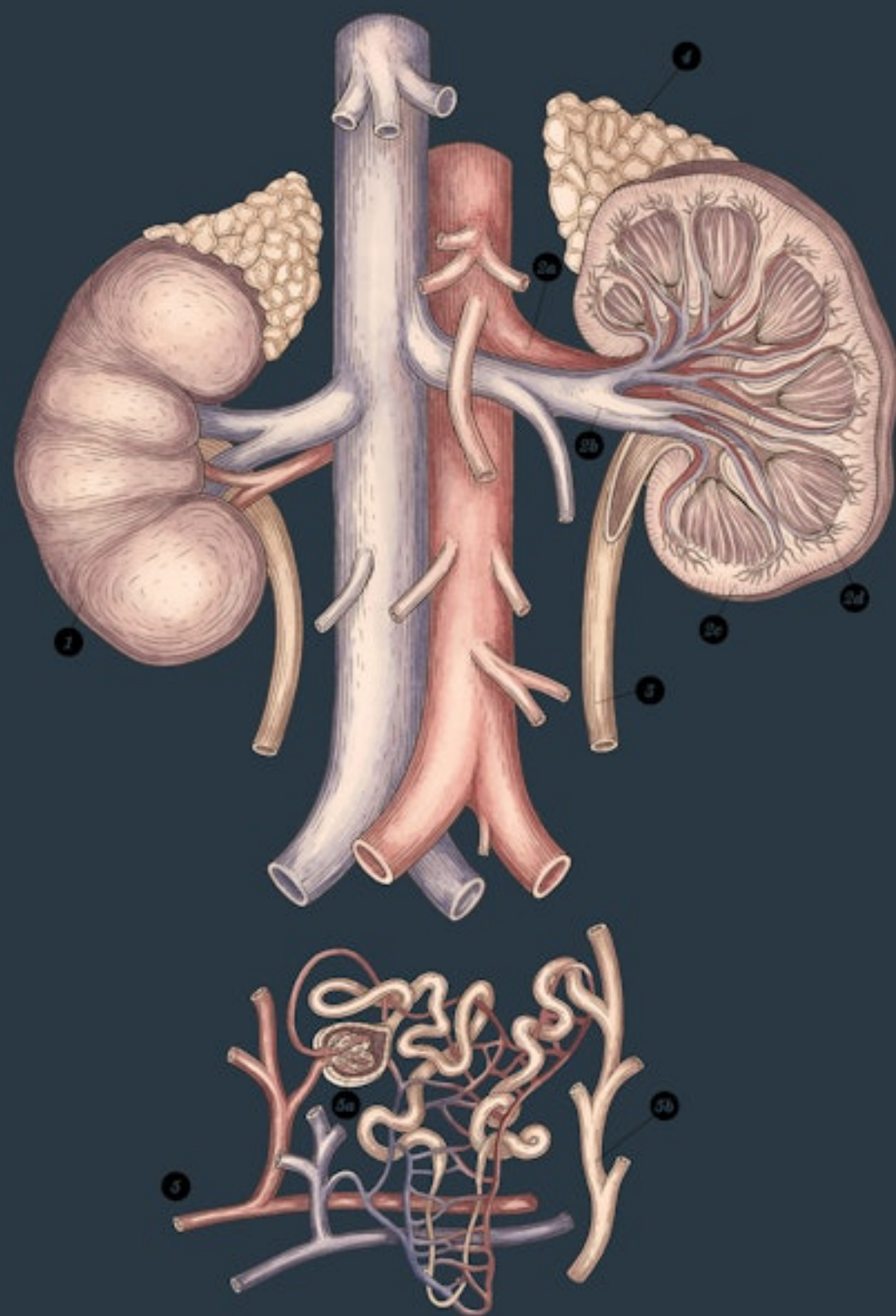
Glands that are part of the endocrine system and are responsible for producing hormones such as adrenaline and noradrenaline.

### 5: Nephron

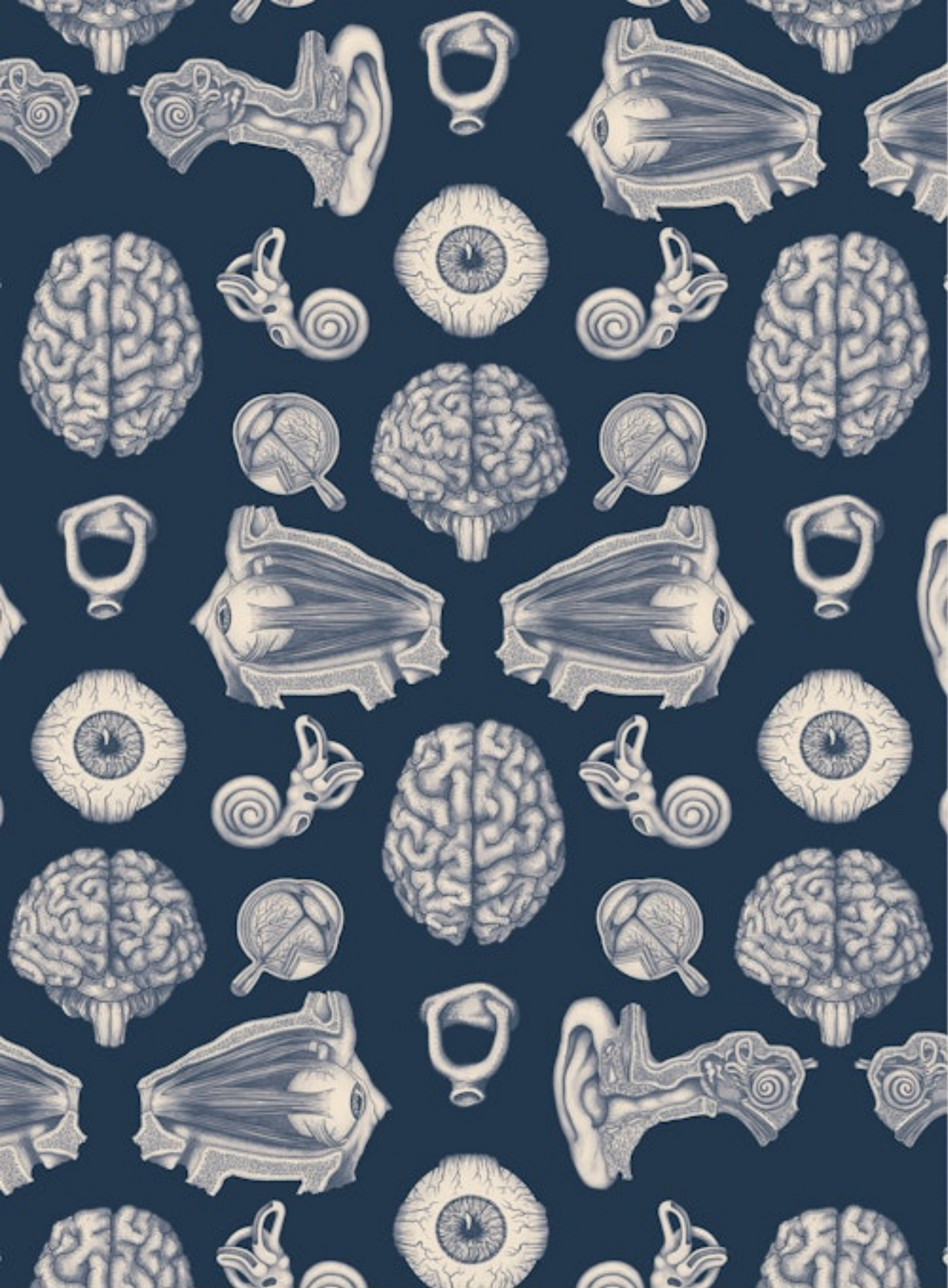These twisted tubes are the filtration unit of the kidney where urine is made.

**a)** The glomerulus: Blood is filtered through a sieve-like structure called the glomerulus, then into the rest of the nephron.

**b)** Collecting ducts: Urine is collected in tubes which direct the fluid out of the kidney towards the ureter.



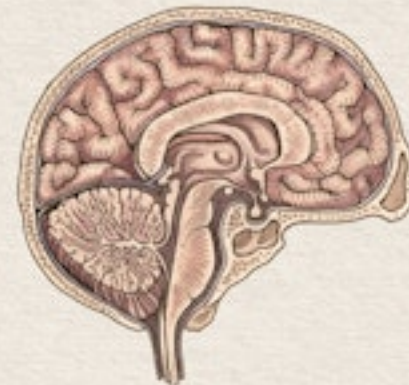



ANATOMICUM

*Gallery 4*

# The Nervous System & Special Senses



*The Nervous System*  
*The Central Nervous System*  
*The Peripheral Nervous System*  
*The Eyes*  
*The Ears*  
*The Nose & Tongue*  
*The Skin*



# The Nervous System

All but the most simple animals have a nervous system – a complex network which processes and relays information around the body like an electrical switchboard. Humans possess the most advanced nervous system we know of, and for this reason we are the only species in the animal kingdom that can talk, write and build sophisticated machines.

The nervous system weaves through organs and tissues to connect each and every part of the body to its central control centre: the brain. Sometimes described as the most elaborate supercomputer ever known, the brain processes hundreds of thousands of messages a second. These messages – telling you information from the outside world and from inside your body – relay to and from the brain as electrical signals. They travel along pathways called nerves, passing each other like traffic on a busy two-way street. Once the brain has taken in information, it can send a message back to the body in response. For instance, if a car appears as you are crossing the road, your eyes will see the car and send a message to the brain, the brain will process the potential danger, then the brain will send signals to make you step back on to the pavement. Even more impressive is the fact that this exchange will take less than a second to happen, as electrical impulses travel along nerves at speeds of over 100 metres per second.

At the hub of the nervous system are the brain and spinal cord. They make up the central nervous system (CNS), and control most of the body's actions. These vital organs sit well-protected within the skull and vertebrae of the spine. The spinal cord then connects to the peripheral nervous system (PNS), which extends out into the rest of the body and is responsible for collecting sensory messages (from the sense organs), and delivering motor signals (orders to move) between the CNS and other body parts.

## Key to plate

### 1: Central nervous system (CNS)

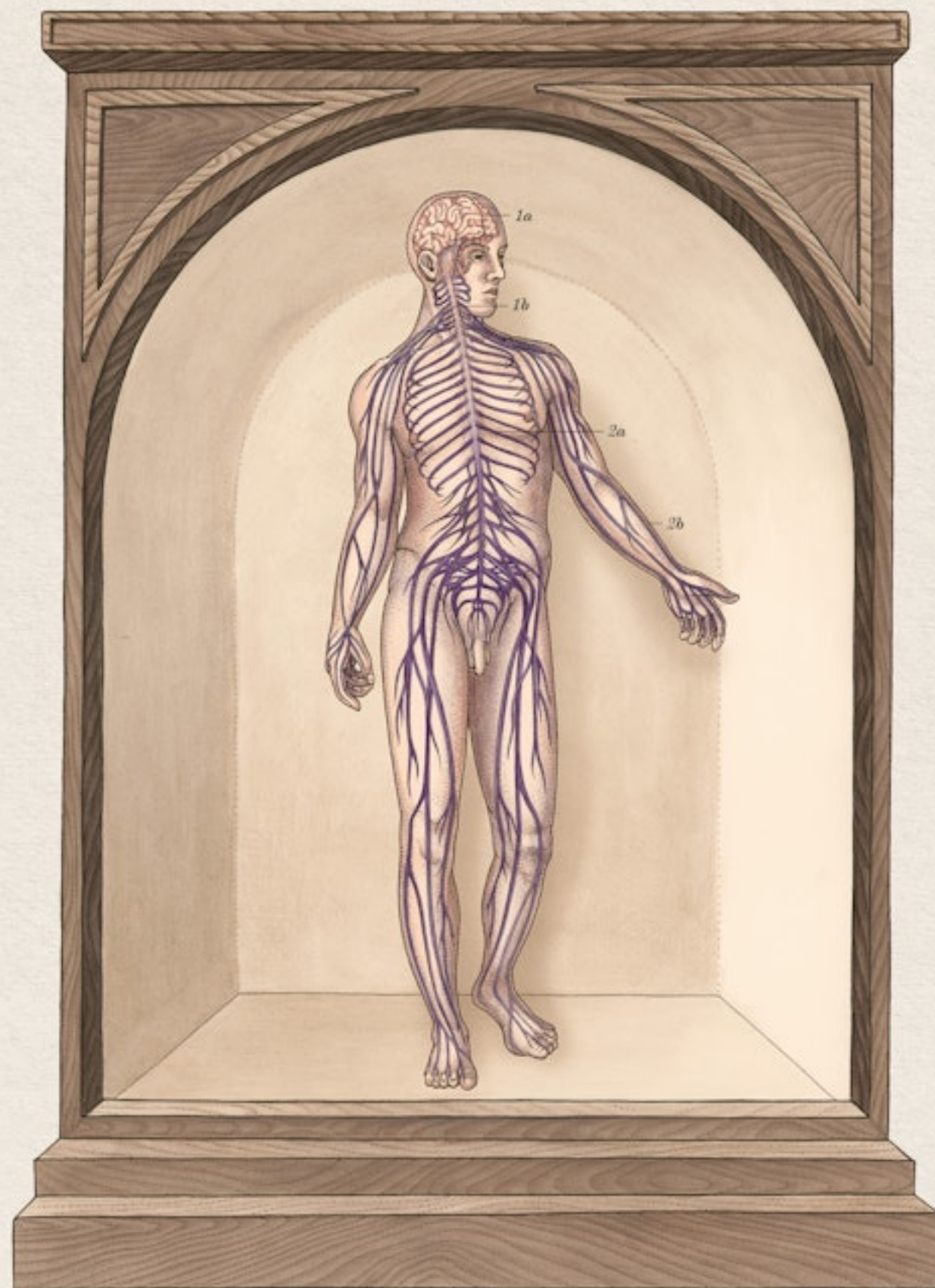
**a)** Brain. This is the control centre for the entire nervous system. All conscious (voluntary) and many unconscious (involuntary) actions go through the brain.

**b)** Spinal cord. This long bundle of nerves connects the brain to the peripheral nervous system.

### 2: Peripheral nervous system (PNS)

**a)** Spinal nerves. The spinal cord branches out to the left and right sides in 31 matching pairs of spinal nerves. Each pair of spinal nerves will supply a specific part of the body and the nerve fibres will travel to and from the brain.

**b)** Peripheral nerves. These run between body organs and the limbs to send messages to and from the brain and spinal cord.





# The Central Nervous System

The human brain is a remarkably complicated organ, and its full complexities are yet to be unravelled. Despite making up just 3 per cent of our overall body weight, the brain uses about 20 per cent of the body's energy – much more than any other organ. This enormous demand for power is because the brain controls everything we do, from movement and breathing to thoughts, emotions and memories.

The brain's outermost part, the cortex, has a wrinkled appearance caused by many folds of the brain tissue. If you were to spread out the cortex, its surface area would be about the size of a newspaper, but because it is folded, the brain's hundreds of billions of nerve cells can fit within the confined space of the skull. Incredibly, the reason our brains are so wrinkled is because they have tripled in size over the course of human evolution! The largest part of the brain is the cerebrum, which is responsible for intelligence plus conscious movements and sensations. It is split into two halves linked by a 'bridge' of tissue: the right side of the brain controls the left side of the body and vice versa. Within each half are areas dedicated to different functions in the body. The earliest discovery that parts of the brain control different activities was the case of Phineas Gage in 1848. An accident resulted in Phineas being injured by a metal rod right through his head. Miraculously he survived and showed no loss of movement or sensory perception. He did, however, have a very different personality. Doctors concluded that the part of the brain the rod had damaged (the frontal lobe) was responsible for character. This view is still held today, and we now know the frontal lobe is important for decision-making, planning, thinking and emotions, which all help to shape our personalities.

Behind the cerebrum, at the very back of the brain, sits the cerebellum, a small, round structure that looks like a walnut and helps coordinate movements and balance. Hanging from the middle of the brain is the brainstem, which connects the brain to the spinal cord. The brainstem also controls the most basic activities needed to stay alive, such as breathing, digestion and pumping the heart. It is constantly firing electrical signals rapidly from the brain to the body and back again.

## Key to plate

### 1: Brain and spinal cord

The spinal cord extends from the centre of the brain. Spinal nerves branch out down the spine forming 31 pairs of nerves that travel to the left and right sides of the body. Each pair will link the brain and spinal cord to a specific body area.

### 2: Brain, seen from the front (anterior view)

The two cerebral hemispheres (halves of the brain) make up the main part of the brain, known as the cerebrum.

### 3: Brain, seen from the top (superior view)

The folds, or gyri, of the brain give a wrinkled appearance. They increase the surface area of the brain.

### 4: Cross-section of the brain

**a)** Cerebrum: The largest part of the brain is responsible for higher order functions such as thinking, learning, decision-making and memory. It is also involved in sensory perception and the control of voluntary movements.  
**b)** Cerebellum: This helps to

coordinate movements and balance.

**c)** Brainstem: This controls activities like breathing, the pumping of the heart and digestion.

**d)** Spinal cord

### 5: Lobes of the brain

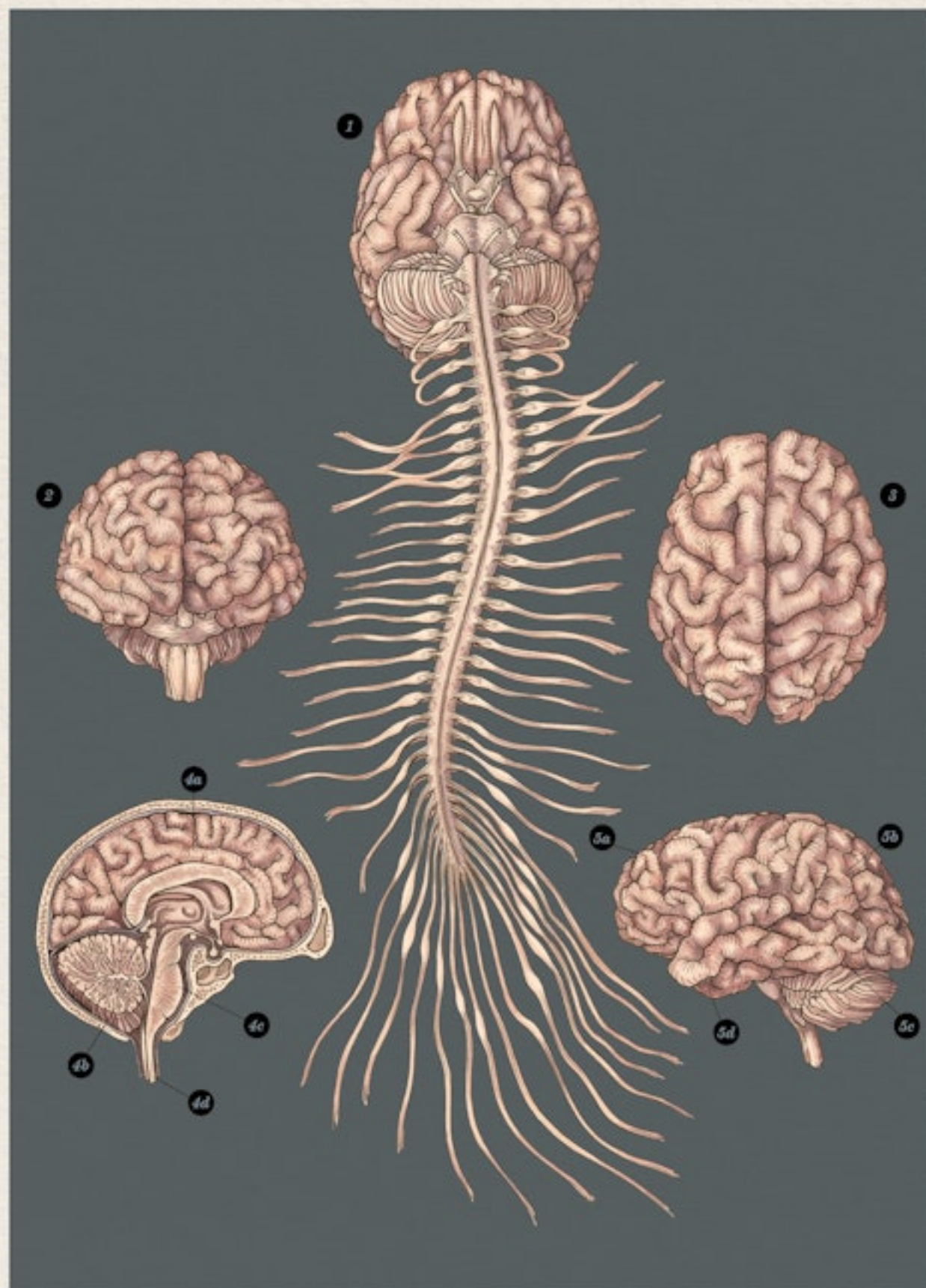
These are named after the skull bones positioned above the different parts of the brain.

**a)** Frontal lobe

**b)** Parietal lobe

**c)** Occipital lobe

**d)** Temporal lobe





# The Peripheral Nervous System

Individual nerves are made from bundles of thin nerve cells (neurons), which run through the body like electrical wires. Most neurons have one main fibre called an axon, which sends outgoing electrical signals. Several smaller fibres called dendrites then collect incoming signals from other neurons. In between individual neurons there are small gaps called synapses. Electrical signals cannot jump across these gaps, so axons release chemical transmitters which leap across them. The dendrites 'catch' the signal and pass it on via their own axon. In this way, signals can be sent at incredible speeds from neuron to neuron.

The longest part of the neuron, sometimes called the 'nerve fibre', is the axon itself. Axons vary in size from less than a millimetre long to more than a metre. Just like electrical wires need a plastic coating to stop their current 'leaking' away, axons also have an insulating layer. This takes the form of a fatty tube, called the myelin sheath, which wraps right around the axon. Any damage to this myelin sheath reduces the ability of nerve impulses to transmit between the brain and the body, as seen in diseases such as multiple sclerosis.

The entire human body contains around 95 to 100 billion neurons. Around 80 per cent of these are in the brain and spinal cord (see page 62), but the remainder are found within the peripheral nervous system (PNS). This network of nerves begins where the spinal cord branches out into 31 pairs of spinal nerves, travelling to the left and right sides of the body. It plays a crucial role in communication between the central nervous system and the body's senses and muscles.

The neurons of the PNS are either sensory or motor. Sensory neurons send information from sense organs such as the eyes and ears to the brain and spinal cord, while motor neurons send messages from the brain and spinal cord to the muscles and glands. The PNS is further divided into somatic (voluntary) neurons, which move the skeleton, and autonomic (involuntary) neurons, which control bodily functions, such as breathing, without us ever having to think about them.

## Key to plate

### 1: Reflex arc

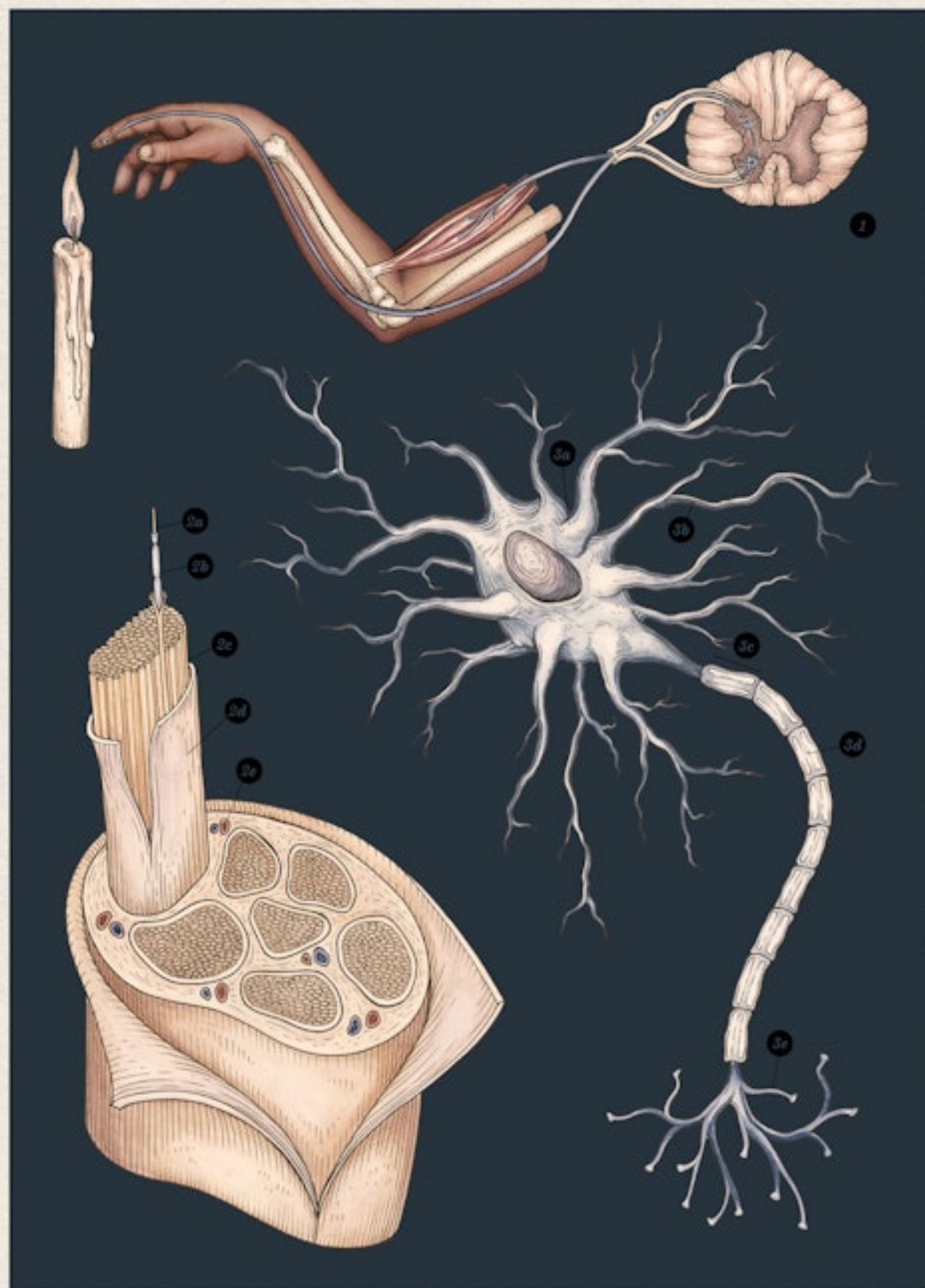
If your hand comes near a candle, pain sensors in the hand will send a message to the spinal cord. The spinal cord will process the danger without sending signals to the brain, and will send motor signals telling the hand to move away from the flame. Reflex reactions enable the body to react at the first sign of danger.

### 2: Anatomy of a spinal nerve

- a) Axon: The central part of a nerve along which electrical signals are sent
- b) Myelin sheath: This fatty layer acts as an insulating coating for the axon.
- c) Fascicle: This is the name for a bundle of axons.
- d) Perineurium: This is a coating around fascicles.
- e) Blood vessels

### 3: Close up of a neuron (nerve cell)

- a) Cell body
- b) Dendrite
- c) Axon
- d) Myelin sheath
- e) Nerve ending





# The Eyes

The eyes are a pair of ball-shaped organs, set within the skull in two spherical holes called orbits. Each eyeball is about the size of a ping-pong ball and their job is to receive light and turn this information into electrical signals that the brain can understand as images.

Light enters the eye through a small hole called the pupil the black 'dot' visible in the centre of the eye. This hole is not open to the outside world; a clear shield called the cornea covers the surface of the eyeball, simultaneously protecting the eye and focussing incoming light. Because the cornea has to remain transparent, like a clean glass window, it is the only tissue in the body which does not contain a blood supply. Instead, a thin film of tears keeps the eyes wet and nourished.

Surrounding the pupil is the iris, a ring of pigmented (coloured) muscle that gives eyes their colour and adjusts the size of the pupil. When exposed to bright lights, the muscles of the iris move automatically, making the pupil much smaller and reducing the amount of light that can pass through. The opposite happens in low light, and the pupil expands to let more light in. After light has entered the eye, it is passed through the lens, a small clear structure that bends the light and focusses it onto the back of the eyeball. Tiny muscles either side of the lens adjust its shape, making it fatter to view objects close by and thinner if objects are further away. If these muscles lose their strength, glasses are needed to help the eye focus the light and stop objects appearing blurry.

The back of the eye, known as the retina, is lined with millions of light-detecting sensory cells. These translate light messages into electrical signals for the brain to receive. About seven million of these cells are a type called cones, which detect colours but are unable to function well in low light. The other 100 million cells are called rods. These are much more sensitive to light, so they work well in low light, though they do not detect colour. This is why scenes appear to be black and white at nighttime. Once the rods and cones have received information, it is finally transmitted to the brain via the optic nerve at the back of each eye. Incredibly this whole process happens in a fraction of a second, and it is thought that the human eye can process nearly 1000 frames, or images, per second.

## Key to plate

### 1: The retina (back of the eye)

Blood vessels cover the back of the eye around the fovea a small pit where the cones are tightly packed, and where light rays are focussed. The back of the eye also contains the optic nerve, linking the eye to the brain.

### 2: The eye muscles

a) Front view

b) Side view

Three pairs of skeletal muscles attach to the outside of each eye, enabling them to move, roll and even cross. Their movements are voluntary, but the coordination of left and right eye movements together is involuntary.

### 3: Iris and pupil

The iris is a ring of pigmented tissue that surrounds the pupil. The pupil is a hole in the centre of the iris. This is where light enters the eye to travel towards the retina.

### 4: Inside the eyeball

a) Cornea This is the clear, outer covering of the eyeball.

b) Iris The pigmented tissue ring.

c) Pupil Where light enters the eye.

d) Lens Where light is focussed.

The shape of the lens can be changed by muscles on either side of it.

e) Vitreous humour A clear, gel-like substance filling the eyeball.

f) Retina The sensory layer at the back of the eyeball.

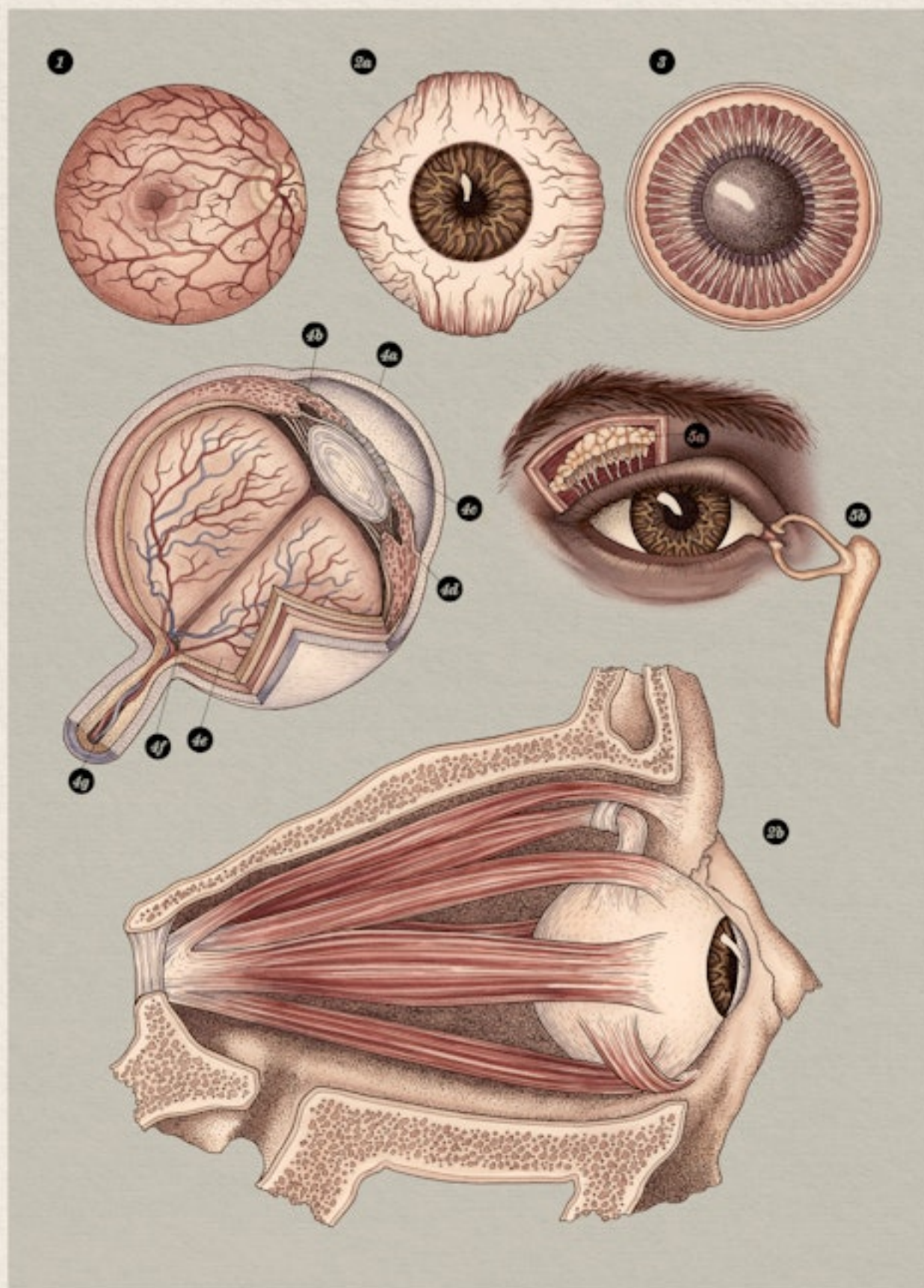
g) Optic nerve This carries sensory information from the eye to the brain.

### 5: Tear production

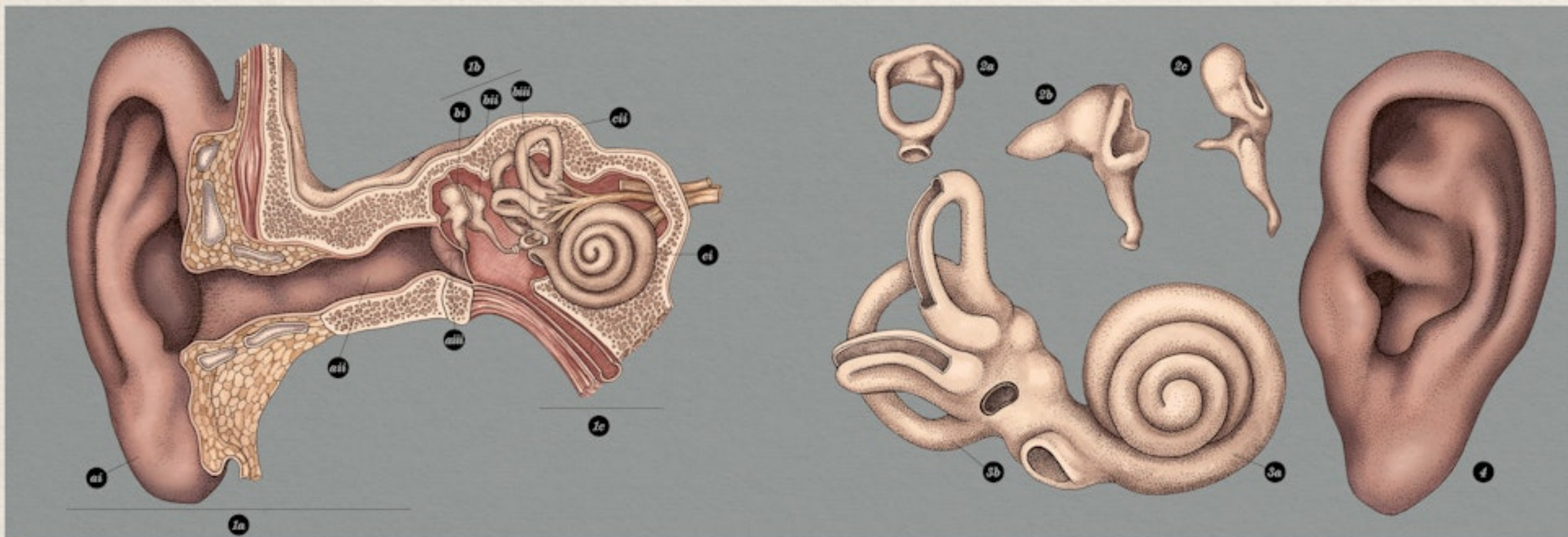
a) Tear (lacrimal) gland

b) Tear duct

eyelashes, eyelids and tear production all protect the eyes from damage. Tears keep the surface of the eyeball wet, and can be used to wash out the eye. This is why eyes begin to 'water' when they become irritated. Excess tears spill out of the eye or drain into the nose via the tear duct, which is why a 'runny nose' is normal when crying.







## The Ears

The part of the ear we can see is in fact just the outer section of an intricate organ that extends deep within our head. Split into three regions, the outer ear, the middle ear and the inner ear, each area has a distinct function. The outer ear's role is to funnel sounds; the middle ear converts sounds to vibrations; and the inner ear converts vibrations to nerve signals the brain can process. Positioned either side of the head, the outer ear is made from a bendy material called elastic cartilage. Its shape collects sounds from all around us and directs them into the ear canal. This 2.5-centimetre passageway leads from the opening on the surface of the skull to the eardrum, a tight membrane that vibrates when sound waves reach it. The eardrum also acts as a physical barrier to stop objects entering the deeper parts of the ear.

On the other side of the eardrum lies the middle ear, an air-filled space containing three tiny but extremely important bones: the ossicles. These bones, called the hammer, anvil and stirrup, connect the eardrum to part of the inner ear called the cochlea. Named due to its resemblance to a snail's shell (cochlea is Greek for 'snail'), the cochlea is a tightly coiled tube about the size of a pea, filled with fluid and thousands of tiny hairs. When sound waves make the eardrum vibrate, the movement passes through the ossicles to the cochlea. The fluid and hairs in the cochlea move, creating electrical impulses that are sent to the brain and de-coded as sounds. Sometimes, the tiny

hairs in the cochlea can get damaged by very loud noises or can deteriorate over time. This is why it is common for elderly people to have problems with their hearing.

Aside from their role in hearing, the ears are also central to our sense of balance. Within the inner ear are a series of thin, rounded tubes called the semi-circular canals. These sit next to the cochlea and are also filled with fluid and more tiny hairs. The fluid and hairs in the semi-circular canals move with every change in position of the head, letting the brain know which way up we are. The brain can then respond to changes in position quickly, and stop us from falling over. This doesn't always work as well as we would hope though, and dizziness occurs when the fluid in the semi-circular canals keeps moving even though we are standing still.

### Key to plate

#### 1: Ear

- a)** Outer ear: This consists of the pinna (**i**), which leads into the ear canal (**ii**). At the end of the ear canal lies the ear drum (**iii**).
- b)** Middle ear: The three smallest bones in the body, the hammer (**i**), anvil (**ii**) and stirrup (**iii**), transmit the vibrations of the eardrum towards the inner ear.
- c)** Inner ear: The cochlea (**i**) and semi-circular canals (**ii**) convert

the vibrations of sound waves into electrical signals for the brain to interpret.

#### 2: Ossicles

- a)** Stapes (stirrup)  
**b)** Incus (anvil)  
**c)** Malleus (hammer)

#### 3: Inner ear

- a)** Cochlea  
**b)** Semicircular canals

#### 4: Pinna (outer ear)

The outer ear acts solely as a funnel for sounds to enter the middle ear. However, it also has some interesting characteristics. The shape of an individual's outer ear is unique to that person, and it has been suggested that the pattern of the ears could be as distinctive as a fingerprint. Also, the outer ears are one of the only parts of the body to continue growing in adulthood, particularly in males.



# The Nose & Tongue

Our senses of smell and taste can detect and recognise a staggering number of substances. For modern humans, these senses are most likely to whet our appetites or to bring back distant memories, but they can also alert us to a potential danger, for example toxic chemicals or rotten food. Even so, they are not usually considered essential. Yet many years ago, our senses were far more important for our survival. The repulsion created by disgusting smells or tastes helped to keep the body safe from life-threatening infections that could be found in faeces (poo), dirty water or bacteria-ridden food, which would once have been daily encounters.

It is thought that the average human can detect several billion different odours. The sense of smell is most sensitive at birth to help newborns recognise their mother. Smell works by detecting odour molecules which float in the air around us. When we breathe, they enter the nostrils and pass into the nasal cavity – a large space behind the external nose. The roof of the nasal cavity contains millions of receptor cells that detect odours and transfer the 'smell' into an electrical impulse. This signal travels to the brain via a connection called the olfactory nerve.

Although our sense of smell is said to be 10,000 times more powerful than our sense of taste, the two are closely linked, and food tastes different if our ability to smell is impaired. This is something you might have encountered before, especially if you've eaten while you have a heavy cold or have pinched your nose while chewing food.

Thousands of taste sensors are found on the top surface of the tongue, on little bumps called papillae. More commonly known as taste buds, these special sensors detect chemicals in the food we eat and send messages to the brain. For many years, there were known to be four basic flavours of food that we can detect: sweet, sour, salty and bitter. More recently, a fifth taste category has been proposed, called *umami*, meaning 'savoury' in the Japanese language.

## Key to plate

### 1: Nose

**a)** External nose: Mostly made of cartilage, the external nose is where odour molecules will enter the nasal cavity through the nostrils (**i**).

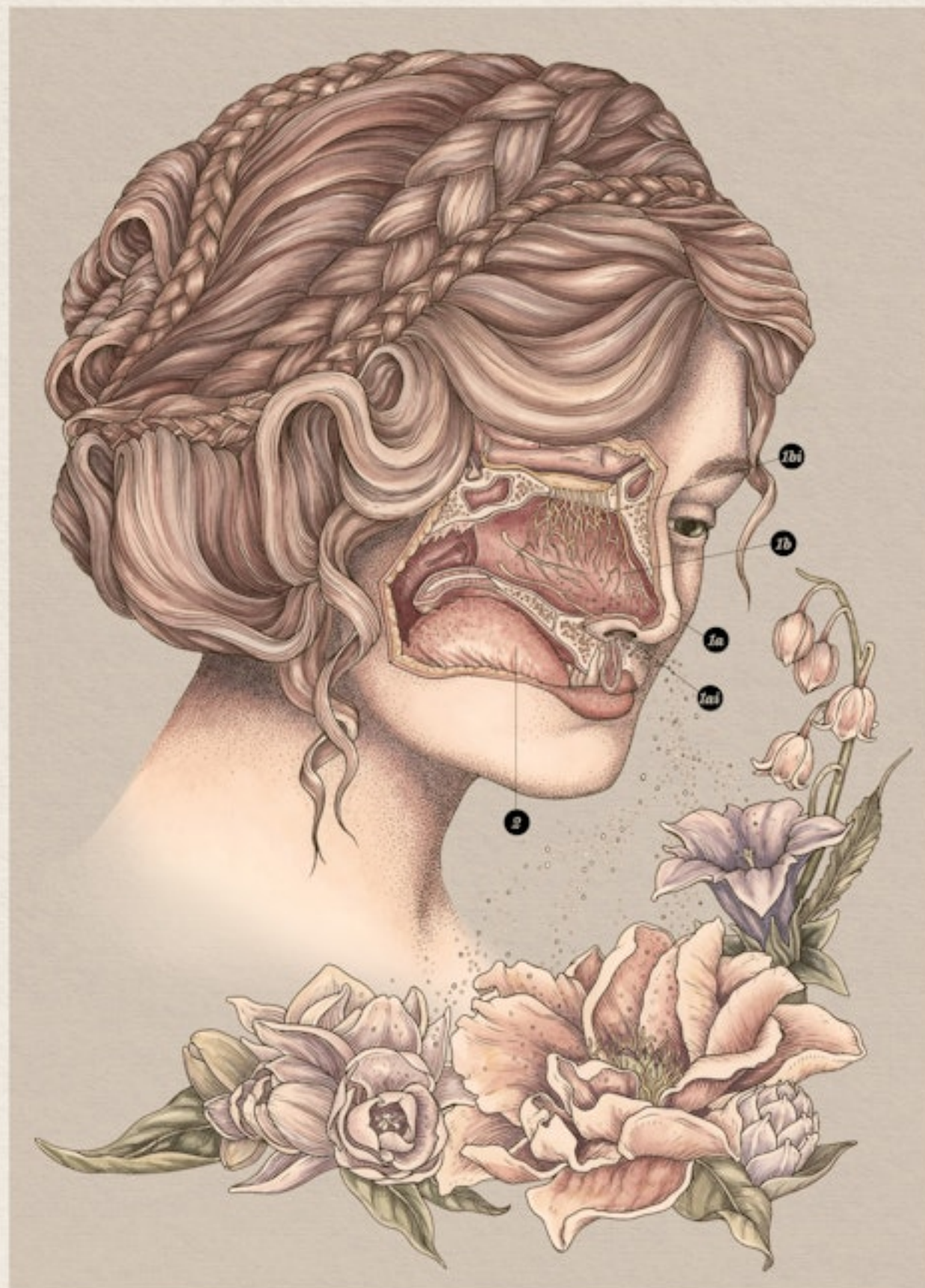
**b)** Nasal cavity: This space inside the skull is home to the olfactory nerves

**(i)** – the nerves that detect odour molecules and transmit the sensory impulse towards the brain.

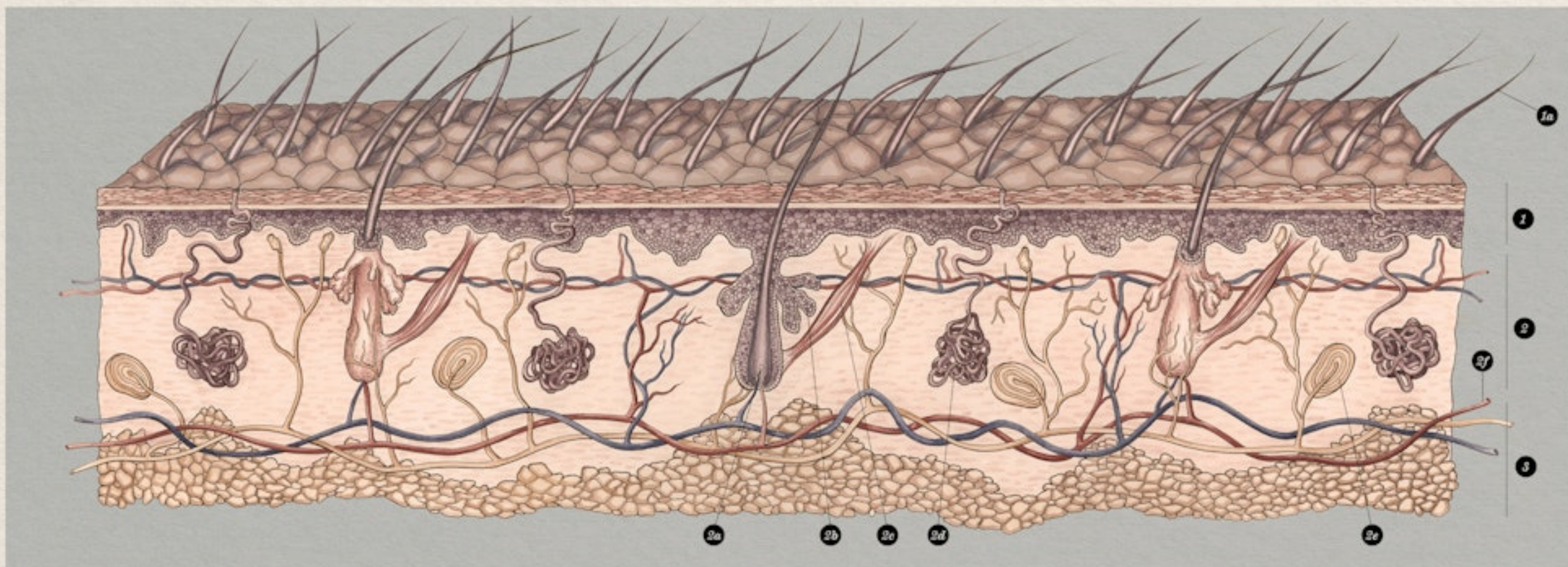
### 2: Tongue

The tongue sits in the oral cavity and is made up of several muscles.

Many thousands of taste buds (or papillae) cover the top surface and are responsible for detecting one of the five different categories of taste sensation: sweet, salty, sour, bitter and umami.







## The Skin

Along with sight, sound, smell and taste, touch is an important sense which lets us experience many different sensations. Tiny touch sensors lie deep within the skin. Forming our whole outer body covering, the skin is part of the integumentary system, a collection of structures including skin, hair and nails, forming a flexible barrier between us and the outside world. Apart from being the most visible body organ, the skin is considered the largest organ both by weight and surface area. Surprisingly, it was often ignored by the early anatomists, and usually discarded to access the organs and tissues beneath. As scientific discoveries progressed, and instruments like the microscope were invented, anatomists were able to explore the skin in greater detail and determine the many important jobs it has.

Skin is made up of two layers. The top layer, the epidermis, is made from several sheets of skin cells, creating a protective, waterproof wrapping around the body. Skin cells in the epidermis are always hard at work, growing, multiplying and moving nearer to the surface of the skin as if they are on a conveyor belt. In fact, the very top cells are actually dead, and millions of skin cells fall off each day. Other cells in the epidermis produce melanin, a protective substance that shields the skin from harmful sun rays. When the body is exposed to direct sunlight, the skin may produce extra

melanin in defence, which causes the skin to darken or tan. Underneath the epidermis lies the dermis, a thicker layer made from strong and stretchy proteins. It contains hairs and sweat glands and is home to millions of nerve endings – the sensory receptors that give us our sense of touch. They are found all over the body but are more concentrated in regions such as the face and the fingertips.

Sensory receptors respond to different types of stimuli depending on their type. Mechanoreceptors respond to a mechanical stimulus, such as pressure or vibrations. Sensors that respond to hot or cold temperatures are called thermoreceptors, and those that react to pain are called nociceptors. The final type of sensor are the proprioceptors, which help tell us what position our body is in and therefore help us to coordinate our movements. A sense of touch is crucial for keeping us safe; without it we would not be able to feel our feet on the ground as we walk, to hold and control objects or to feel pain. Pain in particular is crucial to protecting us from harm, as it alerts the body to danger.

### Key to plate

#### 1: Epidermis

The top layer of skin, made from multiple sheets of skin cells

a) Hair shaft

#### 2: Dermis

a) Hair root

b) Sebaceous gland

c) Arrector pili muscle: This pulls hairs upwards in 'goosebumps'.

d) Sweat gland

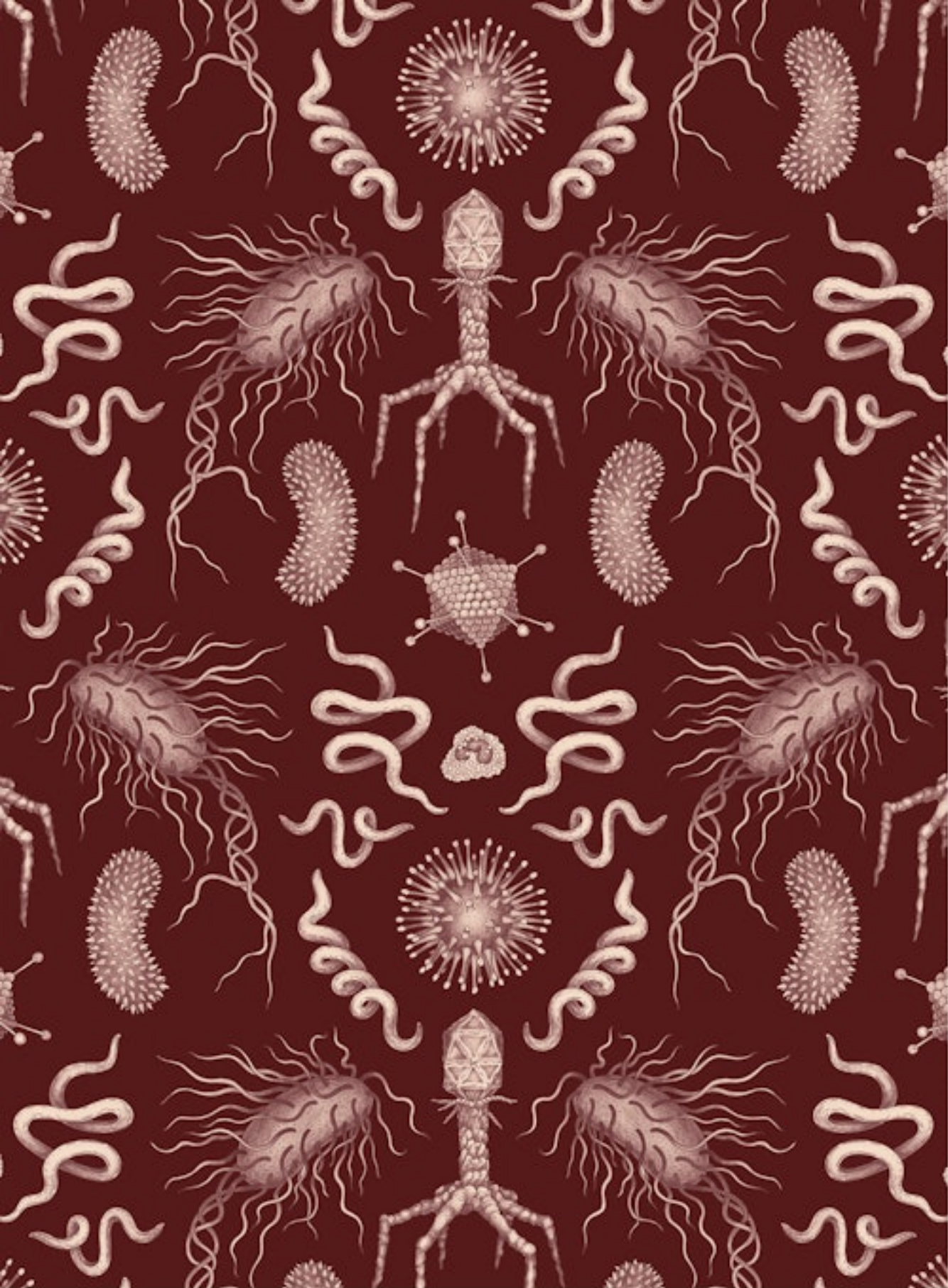e) Sensory receptor

f) Dermal blood vessels

#### 3: Hypodermis

The underlying fat layer

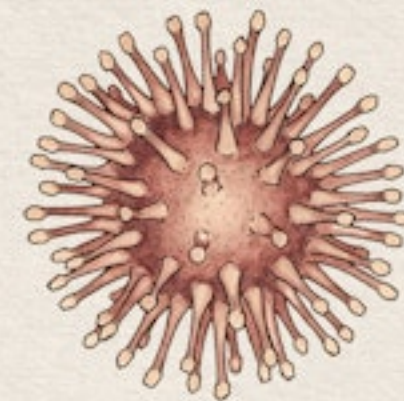




ANATOMICUM

*Gallery 5*

# The Immune & Lymphatic Systems



*The Immune & Lymphatic Systems  
Disease & Defence*



# The Immune & Lymphatic Systems

Imagine an army ready to defend your body from the millions of dangerous germs you encounter every day. This is the immune system, the body's main means of protection. Together with the lymphatic system, it is locked in a constant battle against disease.

The immune system is a collection of organs, tissues and cells that work to defend the body from harmful bacteria or substances that do not belong. A key cell type of the immune system is the white blood cell, also known as a leukocyte. Leukocytes are found in the blood (see page 32) and in areas of disease-fighting tissue, called lymphoid (or immune) organs. These include the thymus, the spleen, the tonsils and the lymph nodes. The largest organ in the immune system is the spleen. It filters the blood, removing old or damaged blood cells from circulation. It also makes leukocytes which produce antibodies (see page 78) to attack bacteria and viruses, and stores blood – holding around a cupful at any one time.

The lymphatic system is made of an extensive network of small vessels that run throughout the body, and lymph nodes, which are clumps of immune tissue found in the neck, armpits and groin. Lymph nodes act like tiny sieves to filter out foreign materials in the body, swelling up if they have trapped invaders and are fighting an infection. As part of the immune system, the lymphatic system helps to tackle disease, but it also mops up excess fluid within the body.

Lymph is a watery substance that comes from liquid squeezed out of the body's cells. A build-up of this fluid would cause parts of the body to swell, so the lymphatic system sucks any excess through tiny, thin-walled lymphatic vessels surrounding blood capillaries. The lymph travels around the body through a network of lymphatic vessels, being cleaned along the way before eventually being emptied into the large veins near the heart. Here the lymph mixes with the blood before being pumped around the body.

## Key to plate

### 1: The tonsils

Three sets of tonsils (lymphoid tissue) in the neck region help to fight infection. These can become swollen when someone has tonsillitis.

### 2: Lymph nodes in armpit

These nodes are small collections of lymphoid tissue in the armpit, neck and groin region. They often swell up if a person is fighting an infection.

### 3: The thymus gland

The thymus is a gland that sits in between the breastbone and the lungs. It is where special defence cells called T-lymphocytes (see page 78) mature. The thymus is most active until teenage years, when it begins to shrink and be replaced by fat.

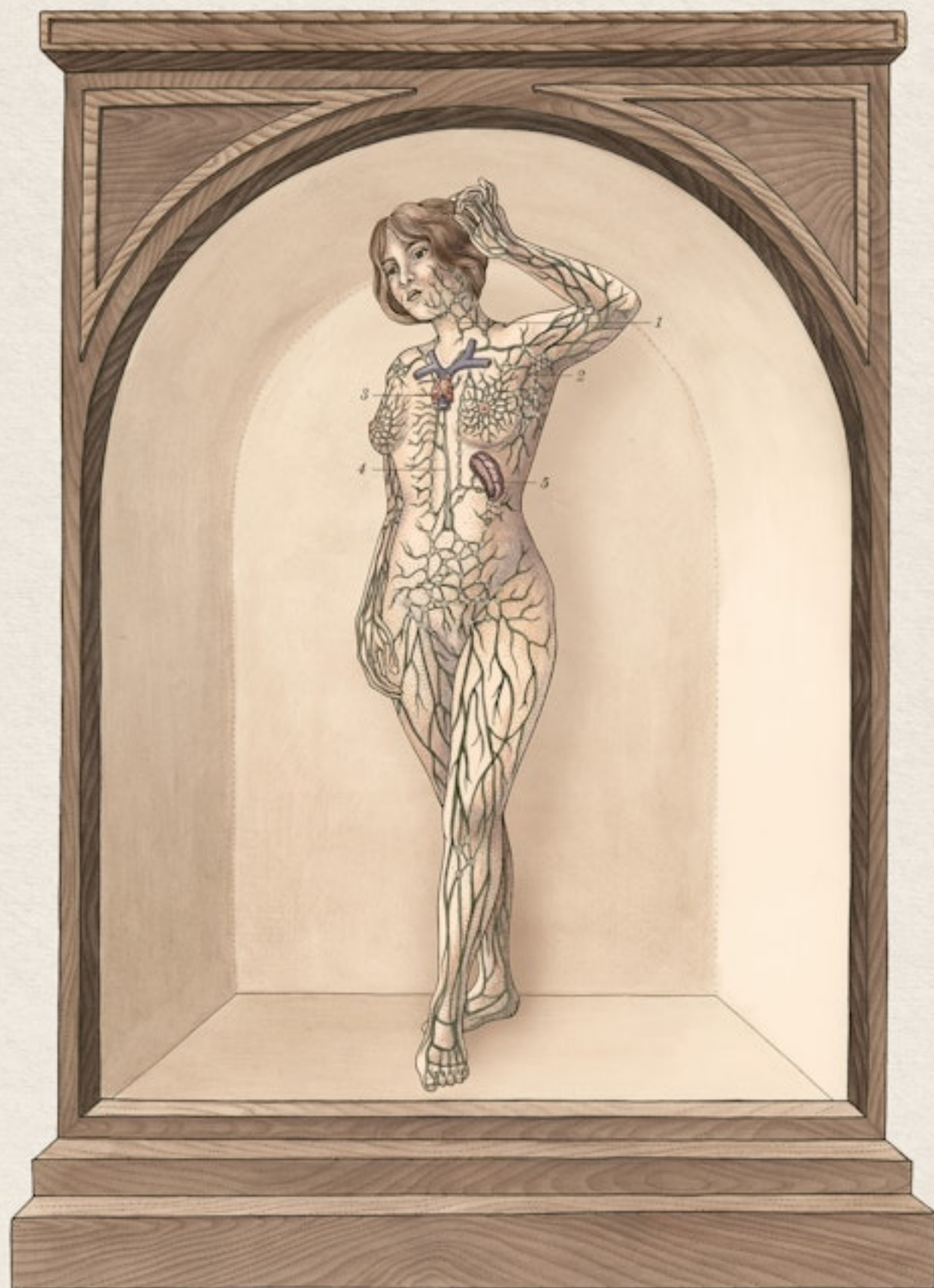### 4: The thoracic duct

This is the largest of the lymphatic

vessels in the body. It transports lymph from the rest of the body to the veins near the heart, where the lymph returns to the circulating blood.

### 5: The spleen

A soft, dark-red organ shaped like a jellyfish. The spleen stores blood, filters it and makes white blood cells.





# Disease & Defence

Microbes, or microorganisms, are tiny living things too small for us to see with the naked eye. They include bacteria, viruses, microscopic animals and fungi, and they can be found all around us. The human body is full of microbes too, many of which are helpful to processes such as digestion. For example, *Lactobacteria* helps to digest the sugars in milk, and *Bifidobacterium* helps the gut work properly. However, some types of microbes are dangerous to our body and can make us unwell. It is the job of the leukocytes (white blood cells) to find these 'bad' bacteria and swiftly remove them.

There are several types of leukocytes, each with different jobs to do. Macrophages are very large cells which destroy foreign objects by 'eating' or capturing them. Their name even means 'big eater' in ancient Greek. A particularly clever variety is the lymphocyte, of which there are two types: T-cells and B-cells. T-cells look for germs that could cause illness, or for abnormal cells with the potential to form disease such as cancer. B-cells, however, produce a protein called antibodies, which stick to the harmful germ like flags to show other white blood cells that the invader needs to be destroyed. The more antibodies produced, the greater the fight against the invader will be, as leukocytes can find and destroy the threat more efficiently. Once antibodies have been produced, the immune system will remember how to fight that invader in the future. This is known as immunity. The body can also build up immunity through immunisations or vaccinations – injections that introduce the body to an inactive form of a microbe. Many serious diseases such as polio and smallpox have been eradicated because of the introduction of immunisations.

Compared to red blood cells, which have a lifespan of about 120 days, white blood cells only last around three days, so they are constantly produced in the bone marrow (see page 10) and released into the blood and lymphatic tissues. The number of leukocytes in the body, called the white cell count, is a good indicator of disease. A low white cell count means a person is susceptible to disease, because the number of cells to fight harmful substances is reduced. A high white cell count often means that the patient has an infection, because white blood cells are multiplying in order to seek out and destroy an invader.

## Key to plate

### 1: Bacteria

- a) Bacilli: These rod-shaped bacteria, such as *E. Coli* (1a), live in the digestive tract and can be single, or join together in long chains.
- b) Cocci: Ball or sphere-shaped, these bacteria exist on their own or joined with other cocci to make diplococci (1b) or staphylococci (1c) bacteria.
- c) Spirilla: Twisted or curved in shape

### 2: Viruses

- a) Helical: Shaped like a tube, these viruses have a thick outer coating
- b) Polyhedral: These viruses are shaped like a dodecahedron with

12 sides. A subset of this virus type are the spherical viruses (2i).

c) Complex: These have a spiralling, helix-shaped tail, and a head with a polyhedral shape. These viruses are called bacteriophages, a class of virus known to only infect bacteria.

### 3: Leukocytes (white blood cells)

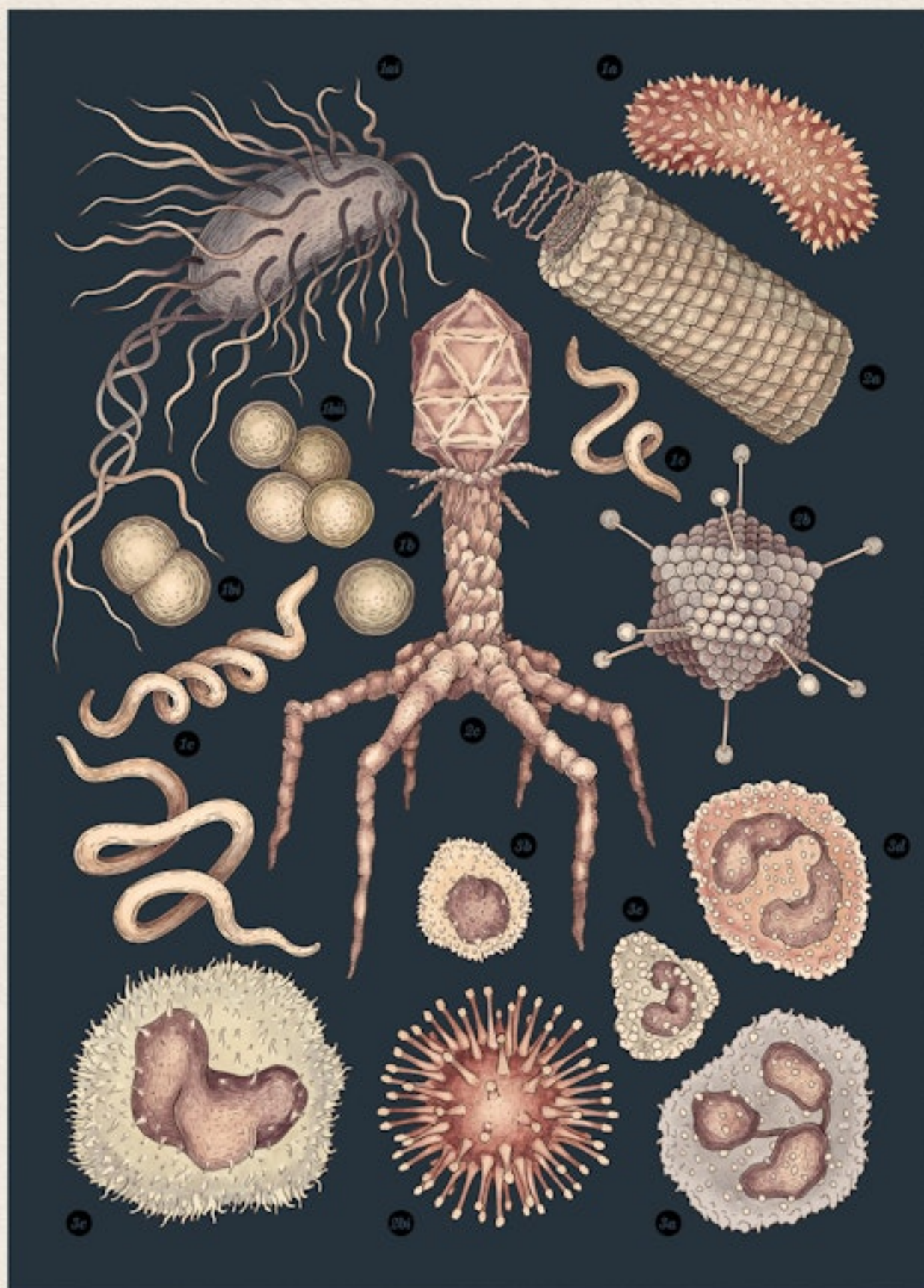- a) Neutrophils: The commonest type of leukocytes, neutrophils make up about 60 per cent of them. They destroy bacteria and damaged tissue.
- b) Lymphocytes: These make up 20–40 per cent of all lymphocytes. B-lymphocytes make proteins called

antibodies that help identify cells to be destroyed. T-lymphocytes attack foreign material in the body such as viruses or cancerous cells.

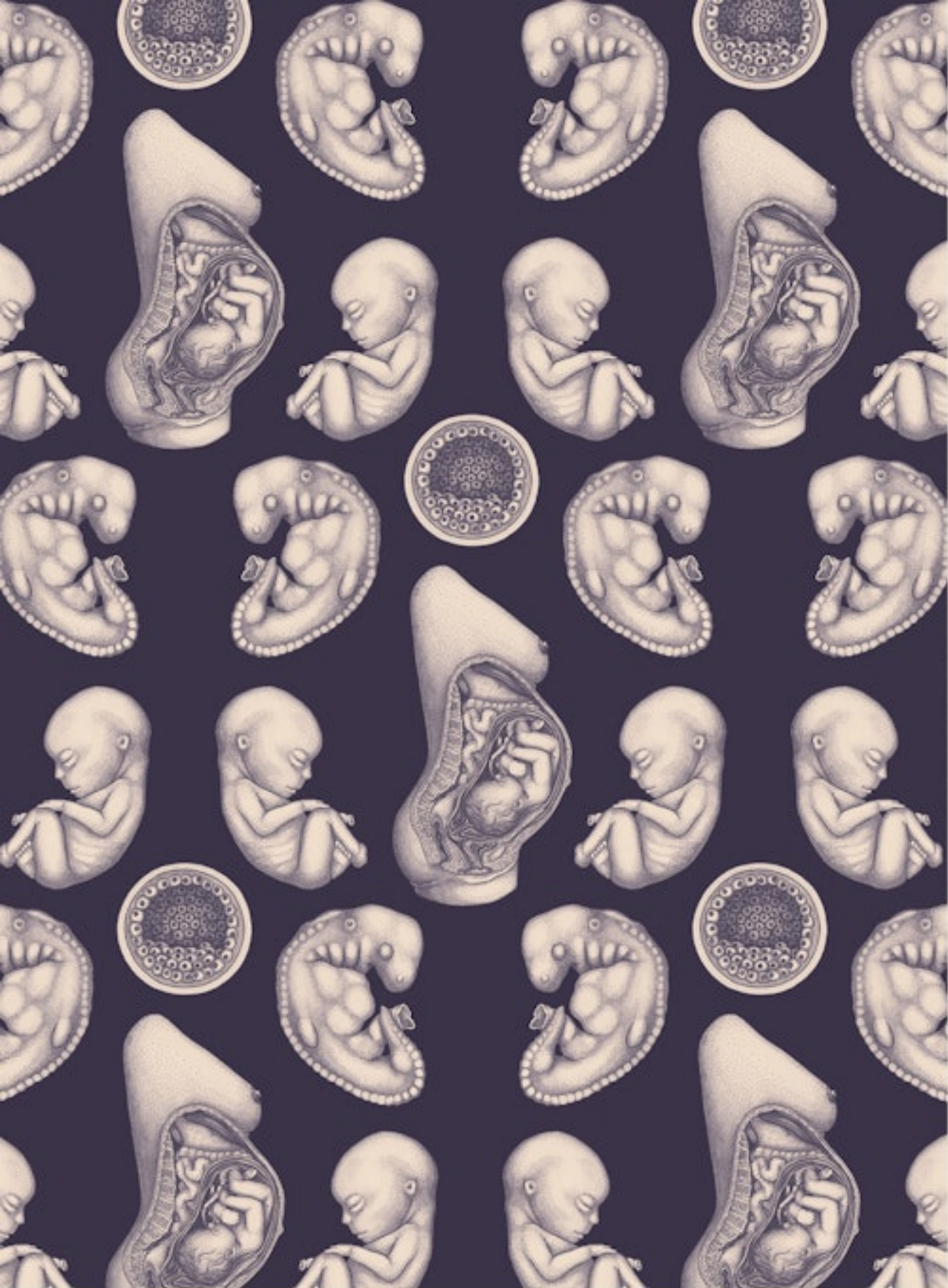c) Monocytes: The largest of all the leukocytes, monocyte cells turn into macrophages that destroy dead cells and bacteria by swallowing them.

d) Eosinophils: These cells help control allergic reactions and destroy parasitic worms.

e) Basophils: The rarest type of leukocyte, these are important in fighting parasitic infections and in regulating allergic responses, such as our responses to pollen or insect stings.



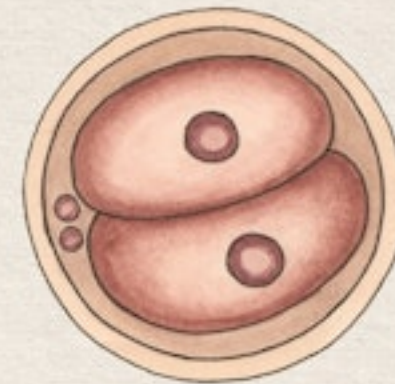




ANATOMICUM

Gallery 6

# The Endocrine & Reproductive Systems



*The Endocrine System*

*Puberty*

*The Male Reproductive System*

*The Female Reproductive System*

*Development of a Baby*



# The Endocrine System

Over 60 different chemical messengers circulate in the blood, delivering instructions to various parts of the body. These messengers are called hormones. They control our growth, our sleep and even our moods. Incredibly, the amount of hormones in our blood can vary depending on age, gender and even time of day! Crucially, hormones enable our body parts to 'talk' to one another – just like the nervous system uses electrical impulses to send messages around the body. The difference is that hormones travel in the blood, so their messages take much longer to be delivered than nervous signals – a bit like the difference in speed between posting a letter and sending an email.

Hormones are produced by specialised cells in the glands and organs of the endocrine system. One of the main endocrine organs is the pancreas, which makes the hormone insulin to control blood sugar levels. If the pancreas is unable to make insulin, the disease diabetes develops and patients need to receive injections of insulin to keep their blood sugar levels under control.

If you have ever been frightened or excited, you will be familiar with the powerful hormone adrenaline. Produced by the adrenal glands above the kidneys, this hormone makes your heart beat faster, your breathing rate increase and your pupils enlarge. You may become pale as blood is diverted away from the skin towards the muscles in your limbs and your body may tense all over. These reactions happen automatically when adrenaline prepares your body to escape or confront danger in what is called the 'fight-or-flight response'. Although usually activated by a physical threat, this intense reaction can have emotional triggers, too.

## Key to plate

### 1: Hypothalamus

This part of the brain sends messages to the pituitary gland, instructing it to produce hormones that affect how you feel and control hunger, thirst and body temperature.

### 2: Pituitary gland

This gland secretes hormones that control growth and development, including the sex hormones which trigger puberty and the maintenance and development of sex cells.

### 3: Pineal gland

This gland in the brain produces hormones that regulate sleep.

### 4: Thyroid gland

Located in the neck, this gland produces hormones that control the metabolism.

### 5: Thymus

This produces hormones that help to keep T-cells (a type of lymphocyte) healthy. The thymus is largest in children, and shrinks during puberty.

### 6: Adrenal glands (or suprarenal glands)

Above the kidneys, the adrenal glands produce 'fight or flight' hormone' adrenaline. They also make hormones involved in regulating blood

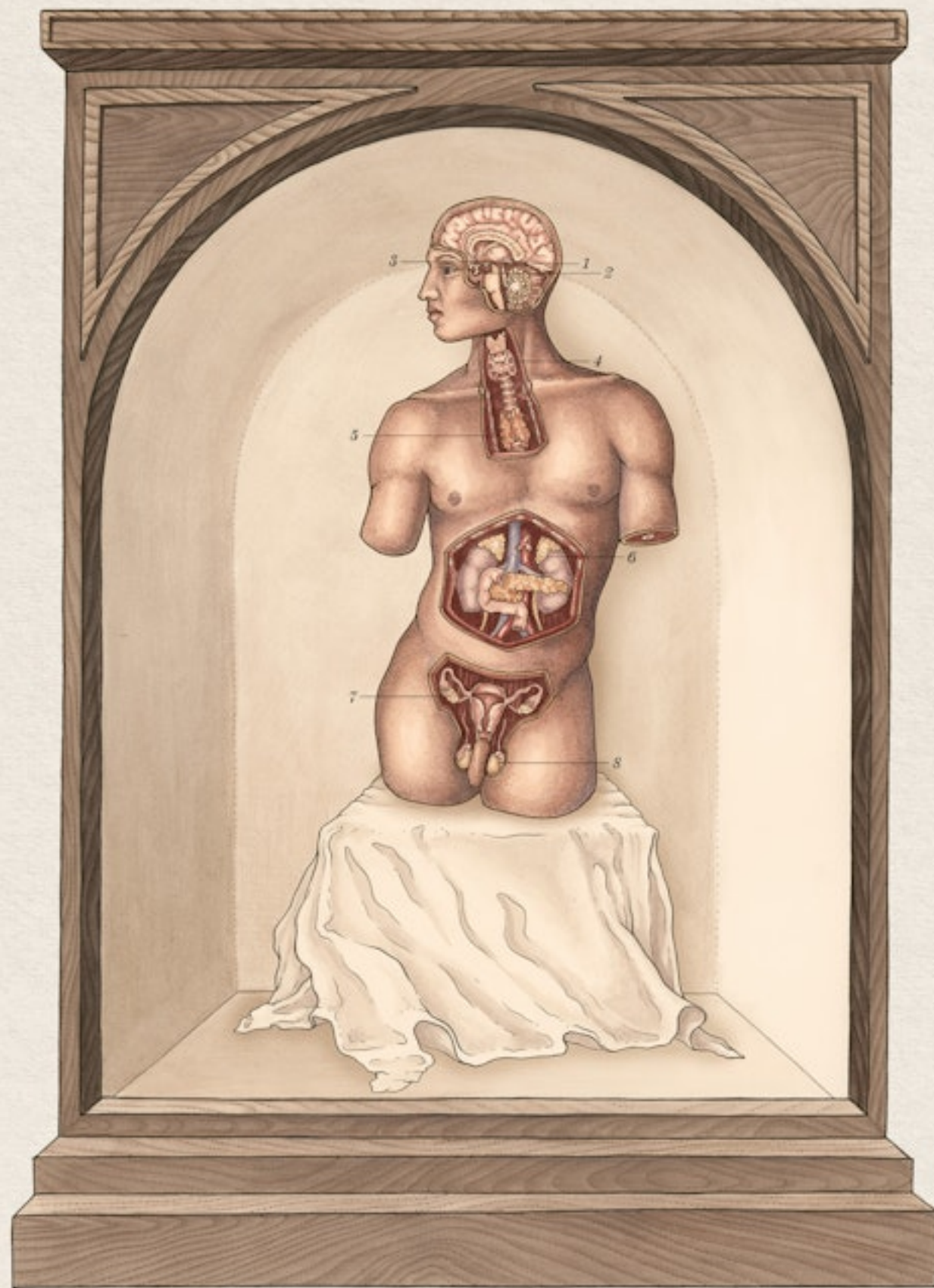
pressure (aldosterone) and stress (cortisol).

### 7: Ovaries (female only)

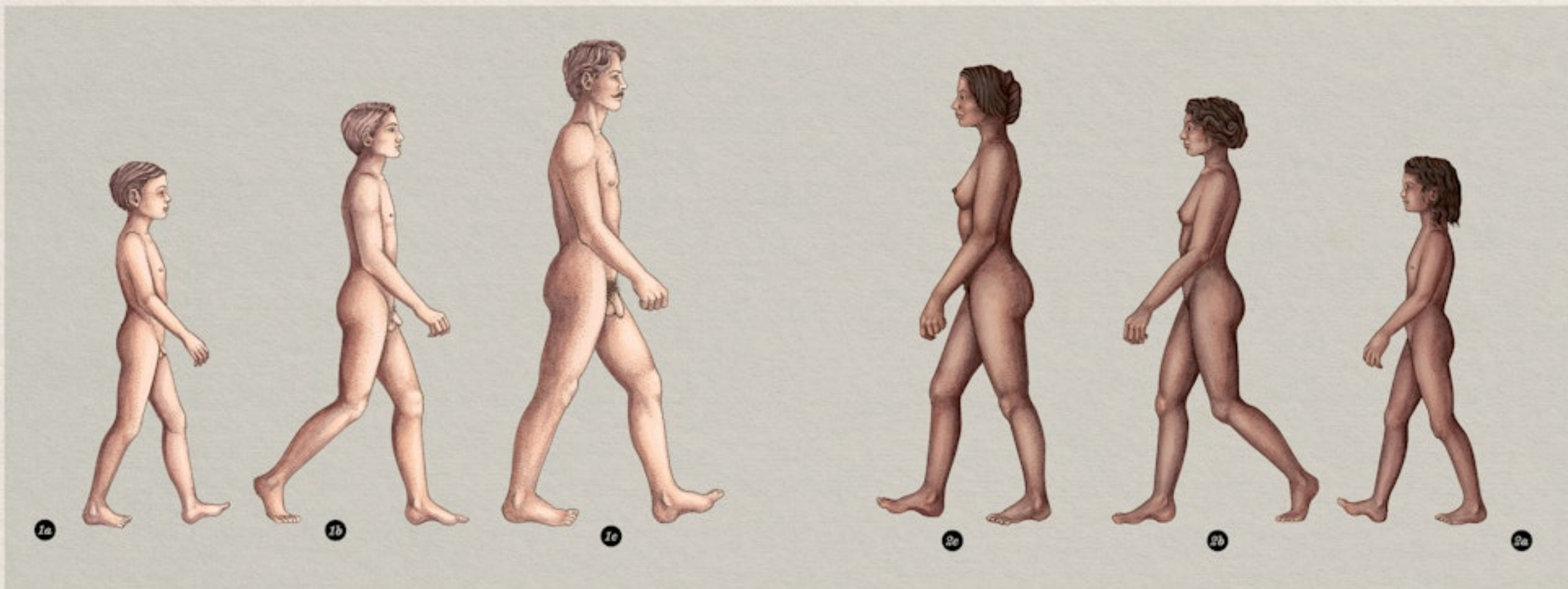
The ovaries secrete female sex hormones, such as oestrogen, that are involved in controlling the female menstrual cycle and in pregnancy.

### 8: Testes (male only)

The testes secrete male hormones such as testosterone, an important substance for sperm production, increasing bone and muscle size and the growth of body hair.







## Puberty

As we transition from childhood to adulthood, the human body goes through an enormous change in growth, appearance and feelings. This transition is called puberty and is triggered by hormones increasing their production and coursing through the body. Puberty can begin any time between about the age of 8 and 14 – it's different for everyone!

Puberty begins when the hypothalamus in the brain triggers the production of hormones by the pituitary gland. One of these is growth hormone, a chemical that makes bones grow in size. This means that during puberty children can have many 'growth spurts', growing as much as 10 centimetres a year! Around the same time, more hormones begin to be produced in other endocrine glands (see page 80), stimulating hair growth in boys and girls. This leads to additional hair appearing all over the body, but in particular around the pubic region and the armpits.

Sex hormones – oestrogen in girls and testosterone in boys – are produced by the reproductive organs, causing them to develop into their mature forms, capable of reproduction (see page 86). In boys the reproductive organs start to make sperm, and in girls the menstrual cycle begins, and the ovary releases an egg every month that can be fertilised to develop into a baby.

The increase in hormones also affects overall body shape, making the differences between males and females more apparent. Boys tend to develop broad shoulders and muscular frames, while girls typically acquire more rounded bodies as their breasts and hips change shape. Boys also find their voice deepens or 'breaks'. Both genders often develop acne as the surge of hormones increases the oiliness of the skin and causes a rise in sweat production. Alongside physical changes, huge fluctuations in hormones also have an effect on emotional responses. Sudden, intense changes in feelings, or mood swings, are common, and people will often begin to form sexual attraction to others.

### Key to plate

#### 1: Transition from boy to man

**a)** Pre-pubescent boy: Overall body shape is similar to female at this age, apart from immature sex organs.

**b)** Around 10–15 years old: Puberty begins. Boys grow taller, their sex organs develop, body hair increases, and the voice deepens.

**c)** Adult body: After puberty, male bodies are typically taller and more

muscular, with fully developed sex organs.

#### 2: Transition from girl to woman

**a)** Pre-pubescent girl: Overall body shape is similar to male at this age, apart from immature sex organs.

**b)** Around 10–15 years old: During puberty, girls grow taller and start to develop breasts. Female sex organs

develop, and the menstrual cycle begins. Hair growth also increases in females and the body shape appears more rounded than males.

**c)** Adult body: After puberty, female bodies have fully developed breasts and sex organs, capable of carrying a baby. In general, female body shape is softer and rounder than males.



# The Male Reproductive System

Every year around 125 million babies are born. Reproduction is nature's way of ensuring a population continues, and an individual's way of ensuring their genes are passed on. It occurs when male sex cells (sperm) and female sex cells (eggs) fuse together as a result of sexual intercourse. These two cells are the start of a whole new life.

The main job of the male reproductive system is to make sperm. Once a male reaches puberty, sex hormones surge through the blood, reaching the testes and triggering sperm production. Hundreds of millions of sperm are made each day. During intercourse, they are released from the testes and travel down the thin tube of the urethra to the end of the penis. Along the way, the sperm mix with other fluids to make a liquid called semen, which then leaves the body quickly during ejaculation.

Sperm can only be made at temperatures a few degrees lower than the normal body temperature of 37°C, so the testes hang outside of the body in a sack of skin called the scrotum. If the testes get too cool, muscles contract to pull the testes closer to the body and warm them up again. Too tiny to be seen without a microscope, sperm are some of the smallest cells in the human body. Each one looks like a little tadpole: it has a 'head' containing all of its genetic information (the instructions that tell cells what to do and what to become) and a tail used to propel it forwards. To fertilise an egg, a sperm has to swim 20 to 30 centimetres through the female reproductive system – a journey equivalent to a human swimming 10 kilometres, or about 200 lengths of a swimming pool. Mitochondria, special cells near the head of the sperm, act like a battery, providing energy as it makes its long journey, while nutrient-rich semen also nourishes it. Up to 300 million sperm can be released at once, but after the first one reaches and penetrates the egg, a chemical reaction in the egg stops any other sperm from getting in.

## Key to plate

### 1: Testes

The two testes are where sperm (male sex cells) are produced within thousands of tiny tubes called seminiferous tubules. The testes sit within a sack of skin called the scrotum.

### 2: Epididymis and ductus deferens

These tubes connect the testes to the urethra (where urine is also carried

out of the body). They transport sperm towards the end of the penis.

### 3: Seminal vesicles

The two seminal vesicles produce fluid that nourishes the sperm and – together with fluid from the prostate gland – makes semen.

### 4: Urethra

This long tube travels through the

penis and is the route for sperm (and urine) to exit the body.

### 5: Penis

Most of the time, the penis is soft as it is made of a spongy type of tissue. During sexual intercourse, the spongy tissue of the penis fills with blood and becomes stiff, making it easier to insert into a woman's vagina and release sperm.

